

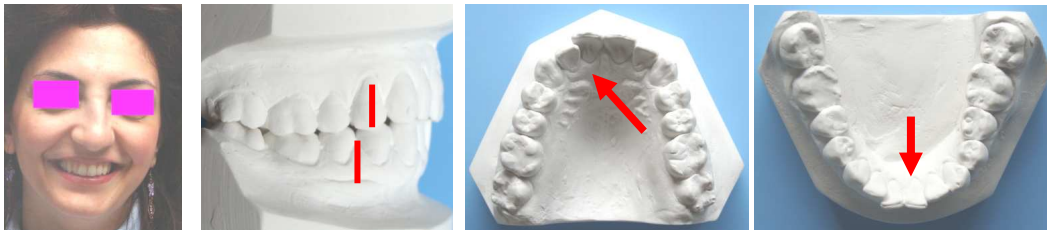2001 – 2011: PUL celebrates its 10th year

Newsletter of January 2011

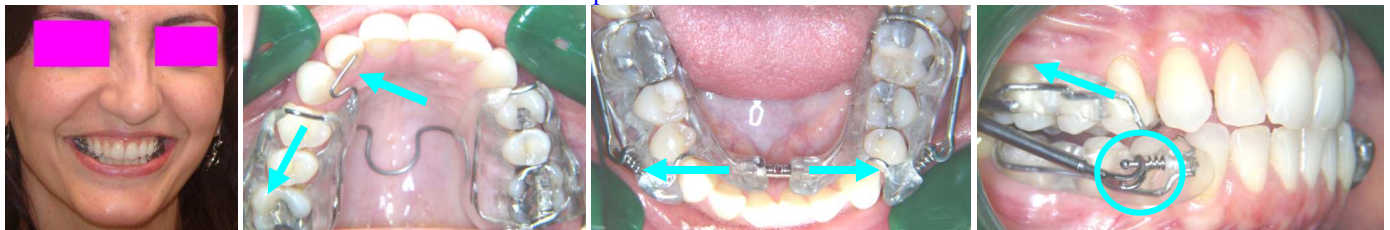
Adult's relapse treatment: usefulness of PUL.

Extracts from lectures «Facial harmonisation : nose-lips-maxilla-mandible »
Callabe-Morin

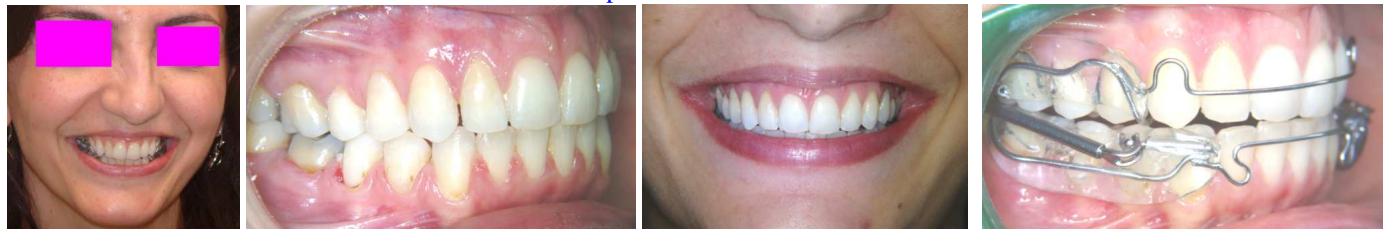Adult's maxillo-mandibular harmonisation : sagittal - transversal – functional



Young women 35 years old: relapse of past orthodontic treatment. Bi-endoalveolar maxillo-mandibular, malpositions and bruxism. Demand is aesthetic and functional : Proposition of PUL multi-function to harmonize the two arches.



PUL in mouth (invisible !) – Correction of endoalveolar maxillae and mandible, distalisation of upper lateral teeth by mandibular anchorage, disparition of bruxism.



After 6 months of PUL, finition by aesthetic low friction braces during 6 months, maintaining the width of the smile.
Fitting of nocturnal 4 D retainer (lingual bonding + PUL anti-relapse).

Indication of PUL in Adult's treatment: Dento-alveolar sagittal and transversal correction. Maxillo-mandibular expansion, distalisation of upper lateral teeth by mandibular anchorage, uprighting mandibular incisors, neutralisation of mastication muscles (bruxism treatment), nocturnal breathing improvement, TMJ friendly thanks to mandibular springs (shock absorbers).

PUL's 4D harmonisation before braces: Correction of 90% of malocclusion with aesthetic appliance reducing the phase of braces to finition only and uprighting radicular axis (without or few elastics) : *more comfort for patient and practitioner..*

Importance of 4 D stabilisation (PUL nocturnal retainer) : Anticipate and prevent relapse which is disturbing for both patient and practitioner, and which economic cost is not insignificant (free retreatment and the image of the office). « *Relapse represents between 10 and 20%. The best way to treat relapses is to anticipate and prevent their apparition thanks to 4D retainer, specially in cases where functional difficulties persists (mouth breathing, atypical deglutition), hyperdivergent Class II growth or hyper-deepbite, cross-bite, overjet, Class III, low position tongue etc...* »

Other extracts on www.pul-ortho.com . Subscribe at Club PUL to receiving news : clubpul-subscribe@domeus.fr