

Classe I II DDM

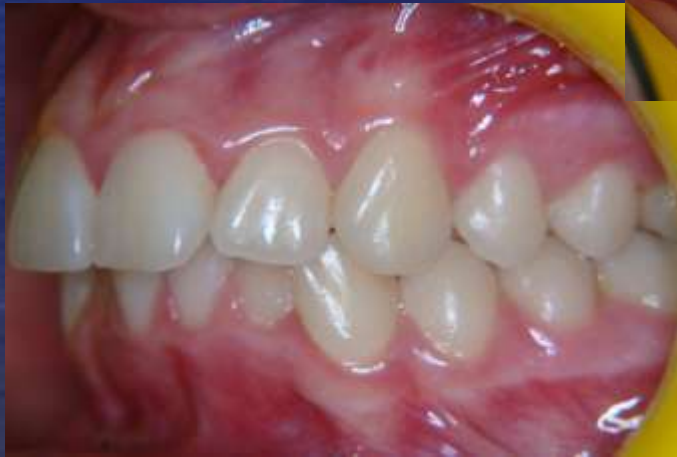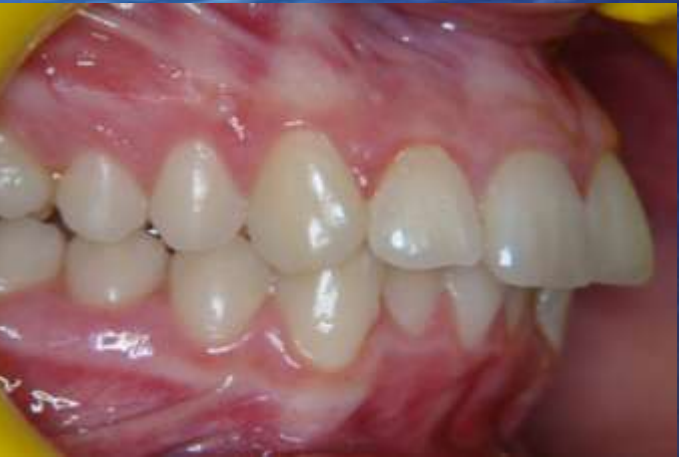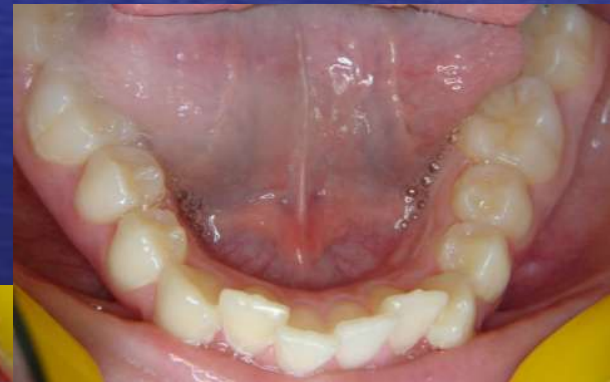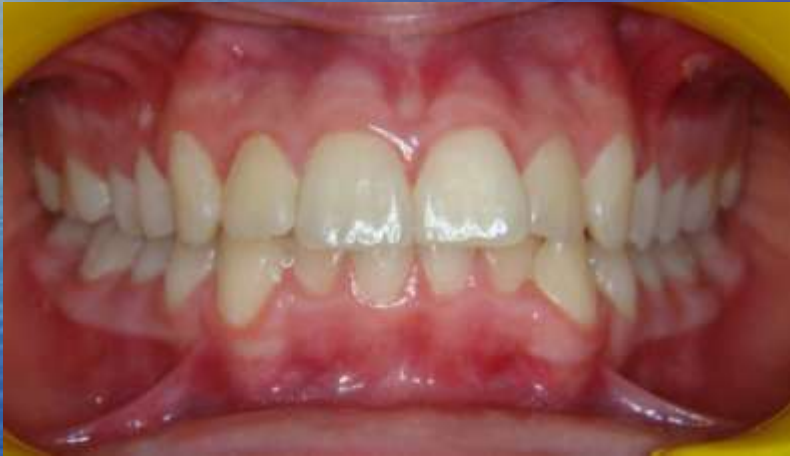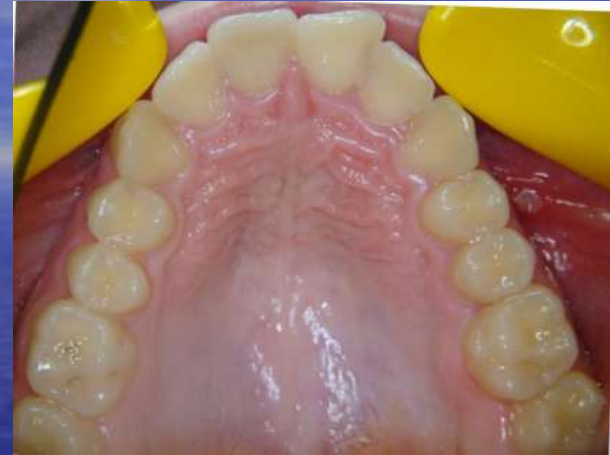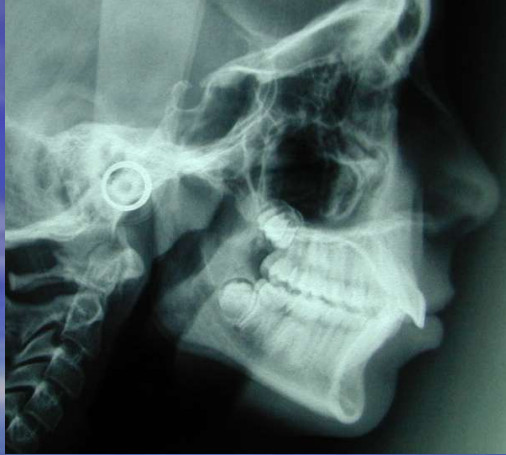Doit-on encore extraire en 2011 ?
Harmonisation des maxillaires
« L'Ancrage mandibulaire »

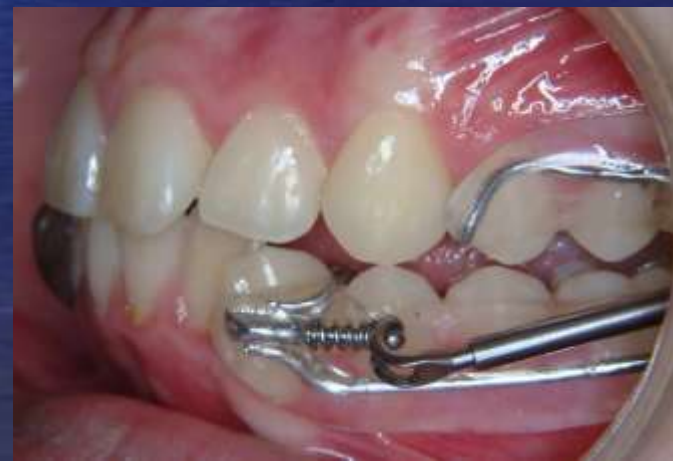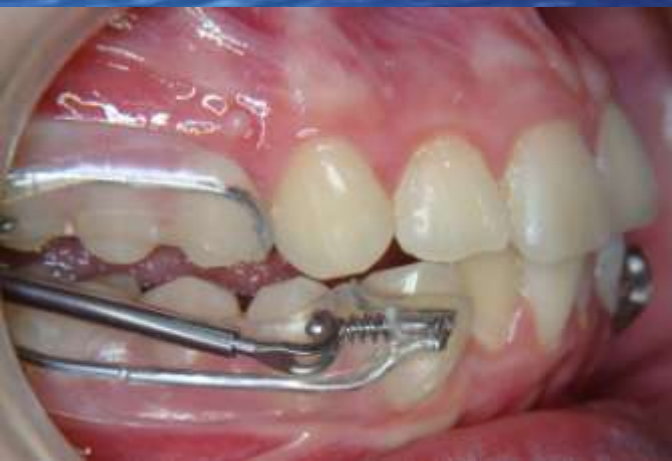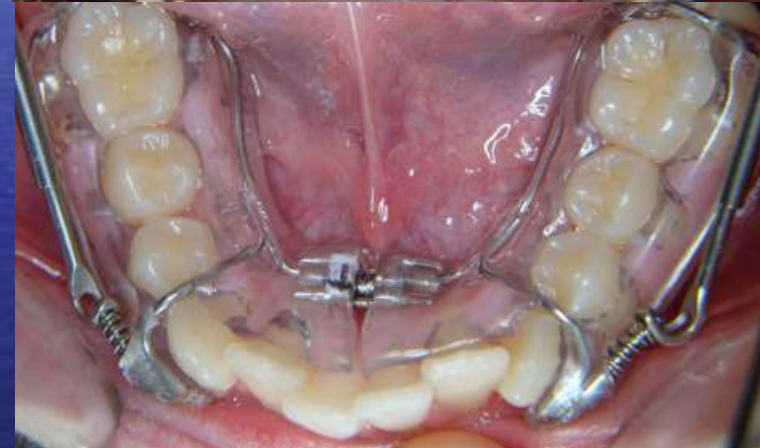
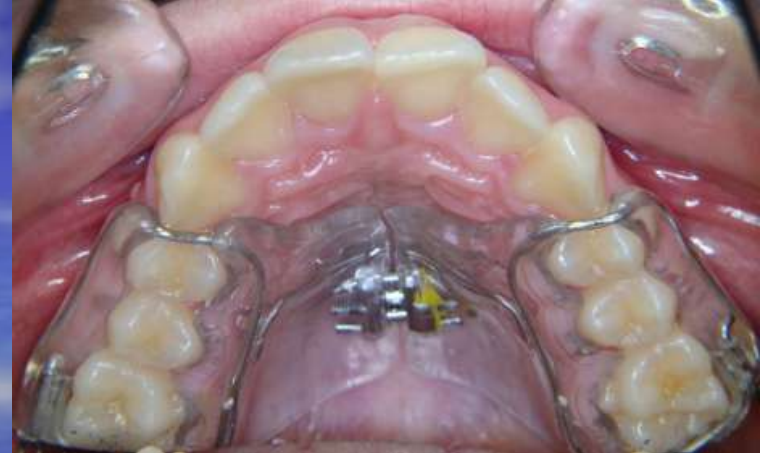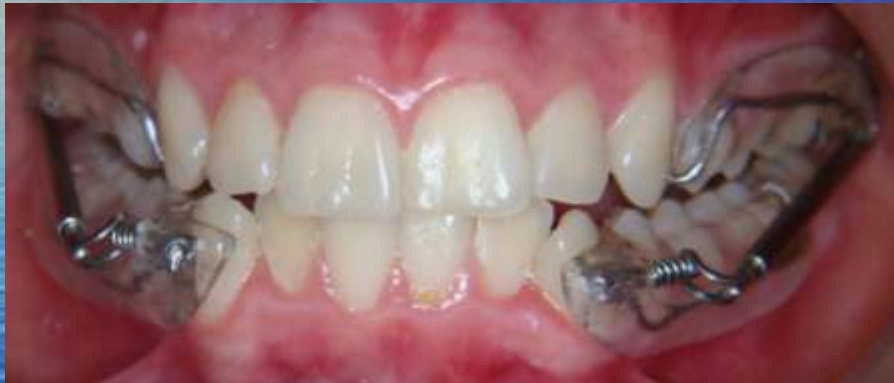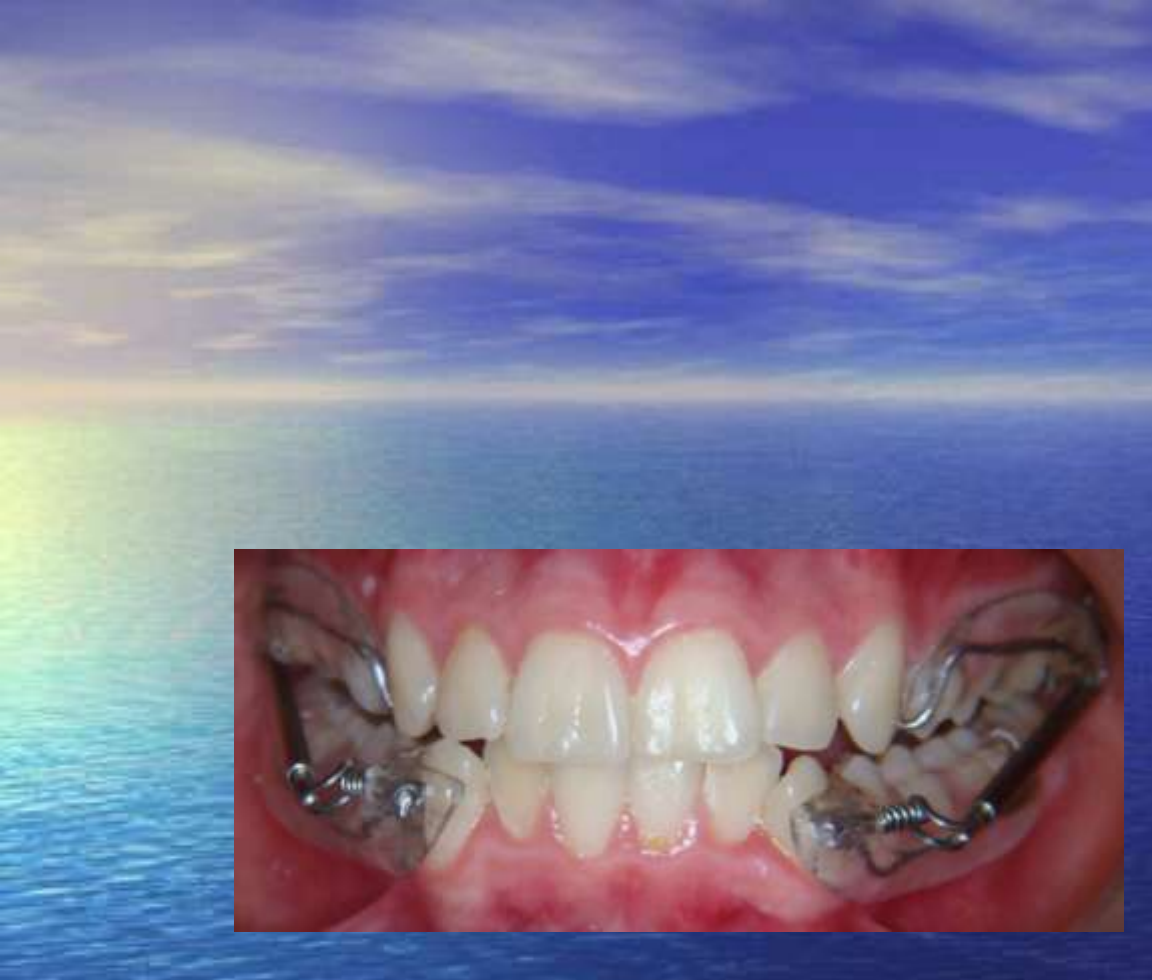Intérêt de la Conjonction PUL + multiattache basse
friction

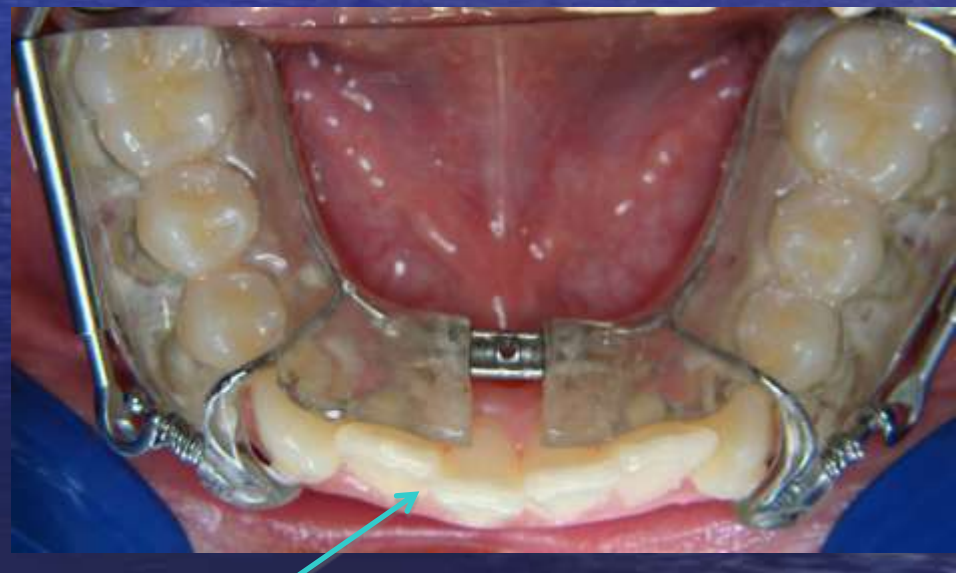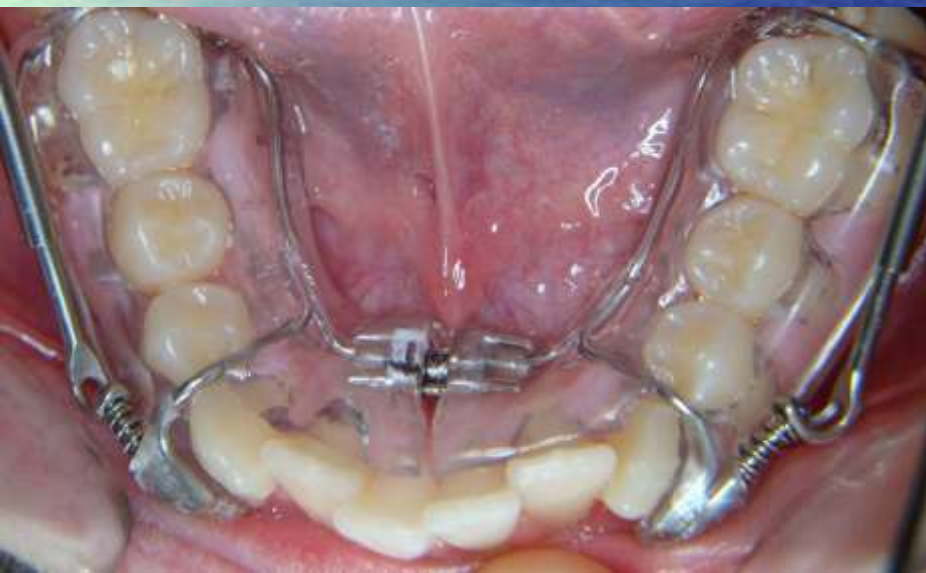
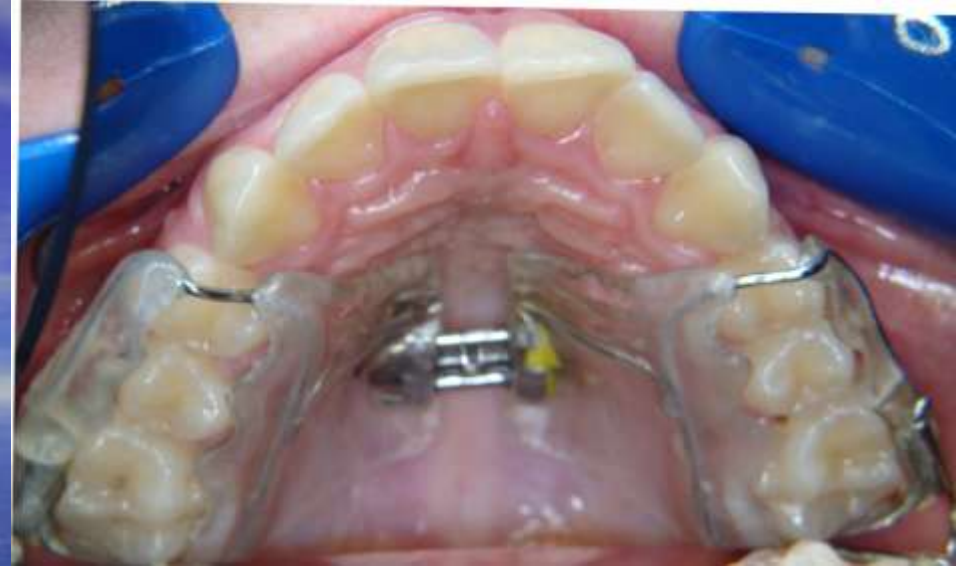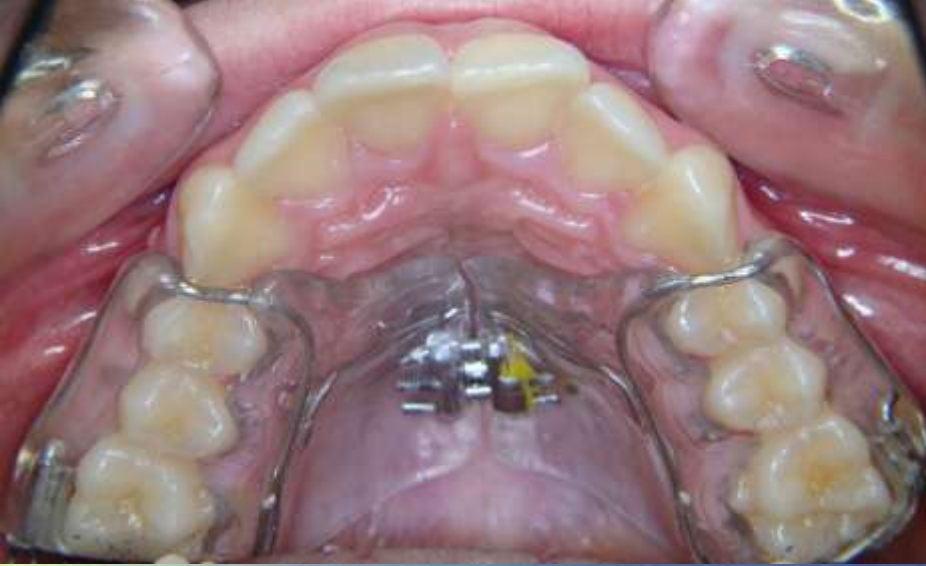PUL Class I Bi-endo Bi-pro

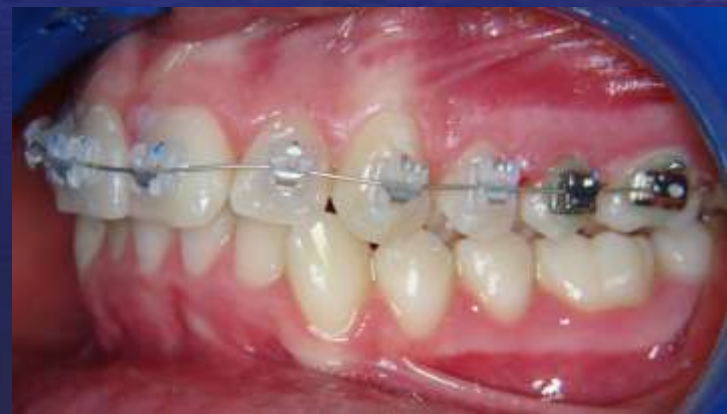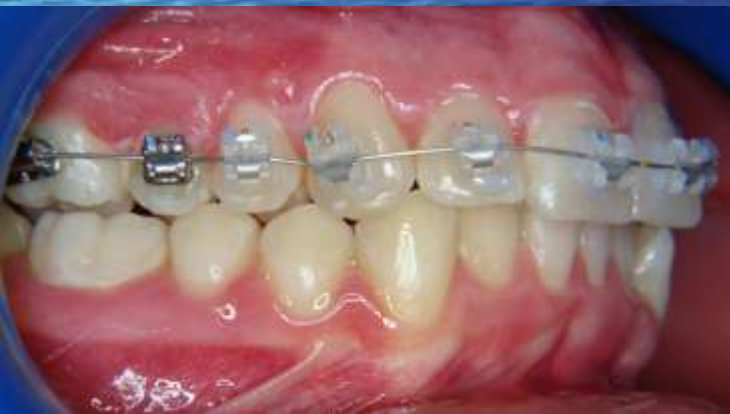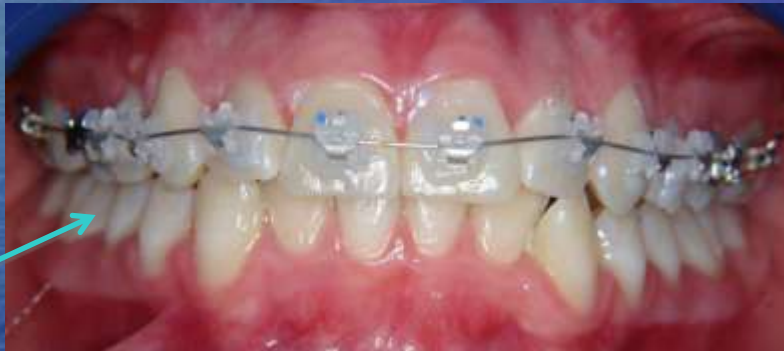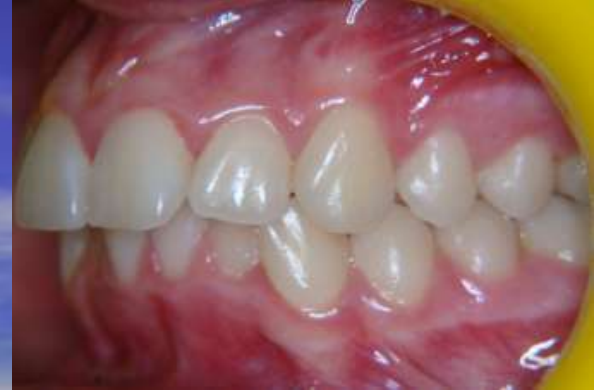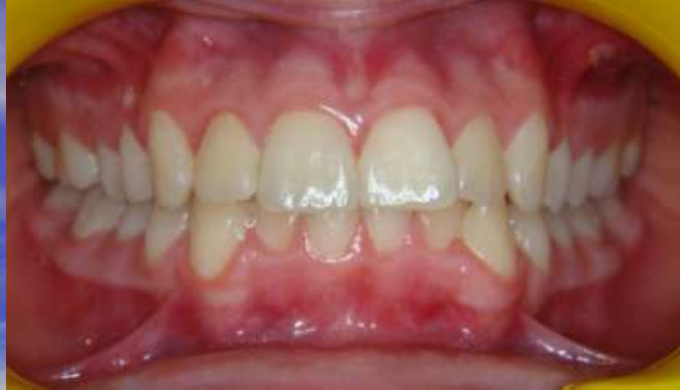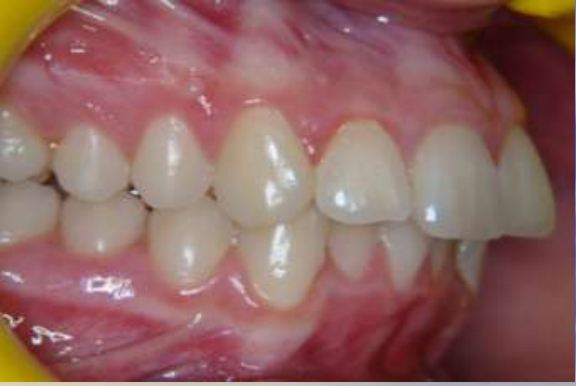Harmonisation 4D

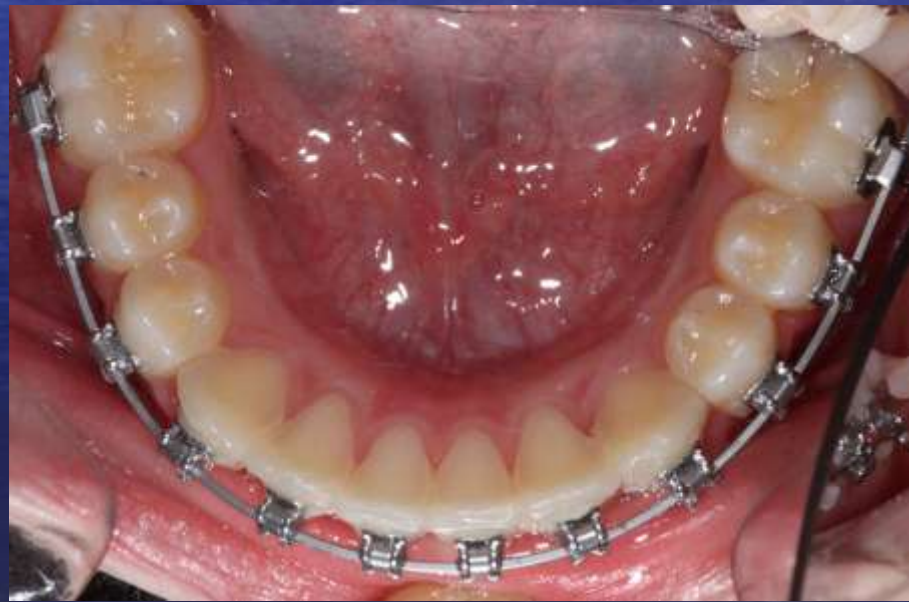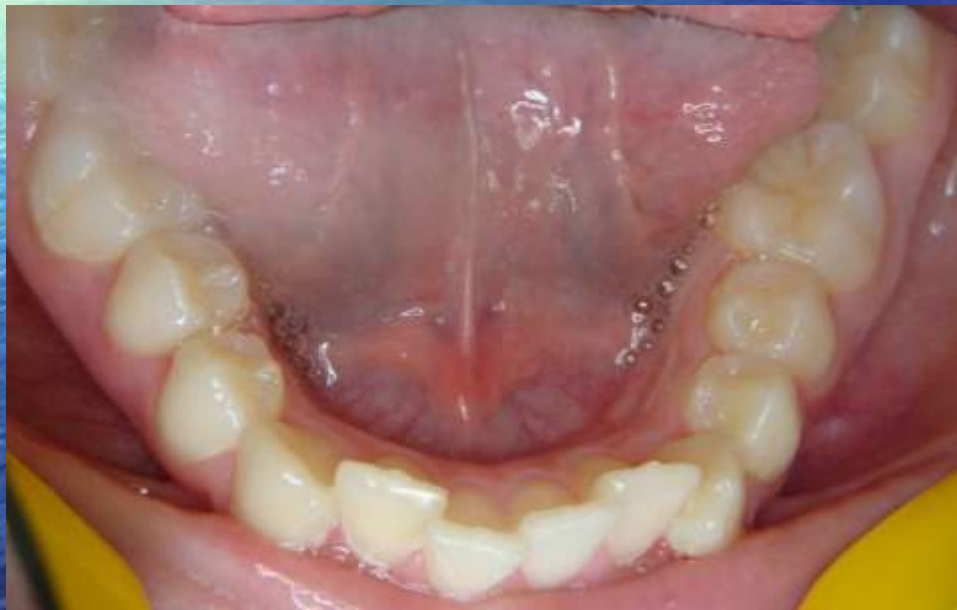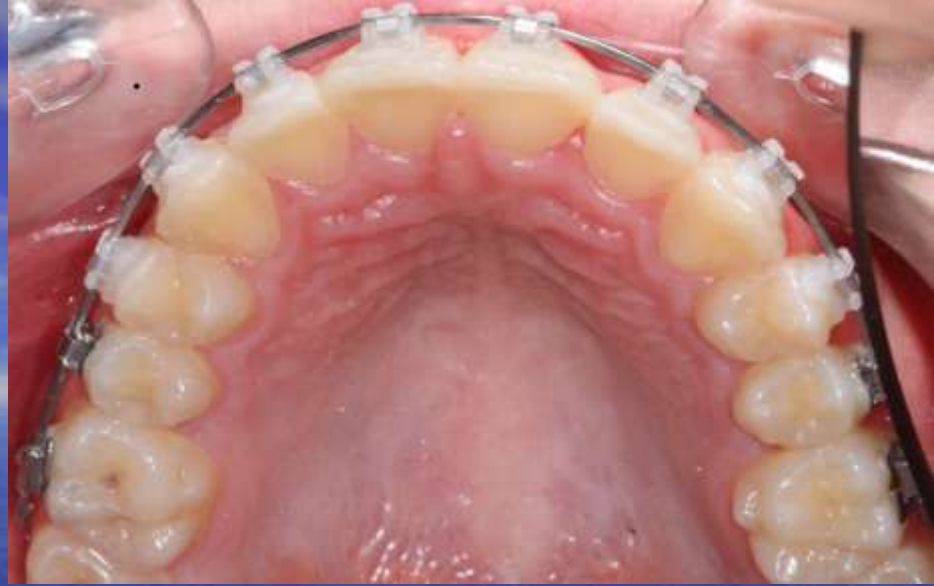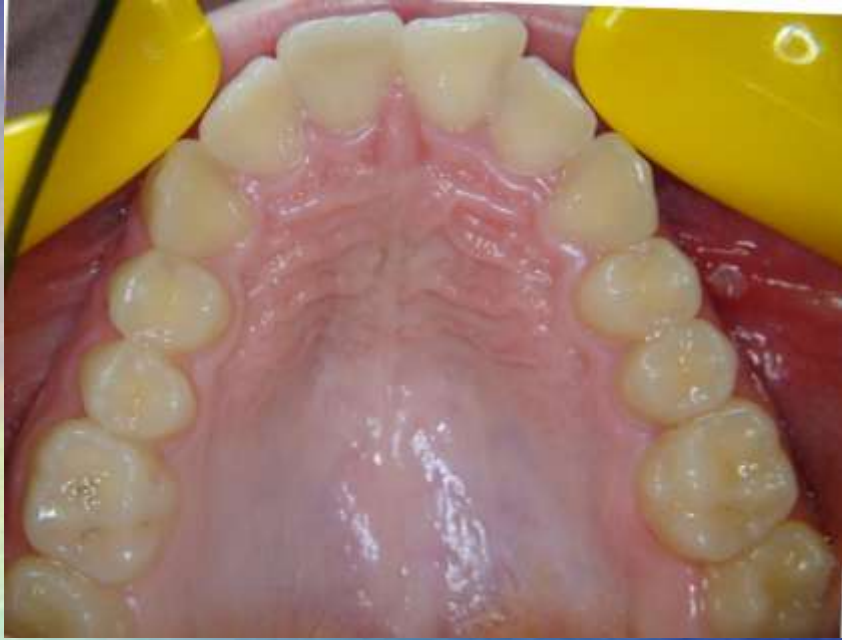Amanda GUIL.

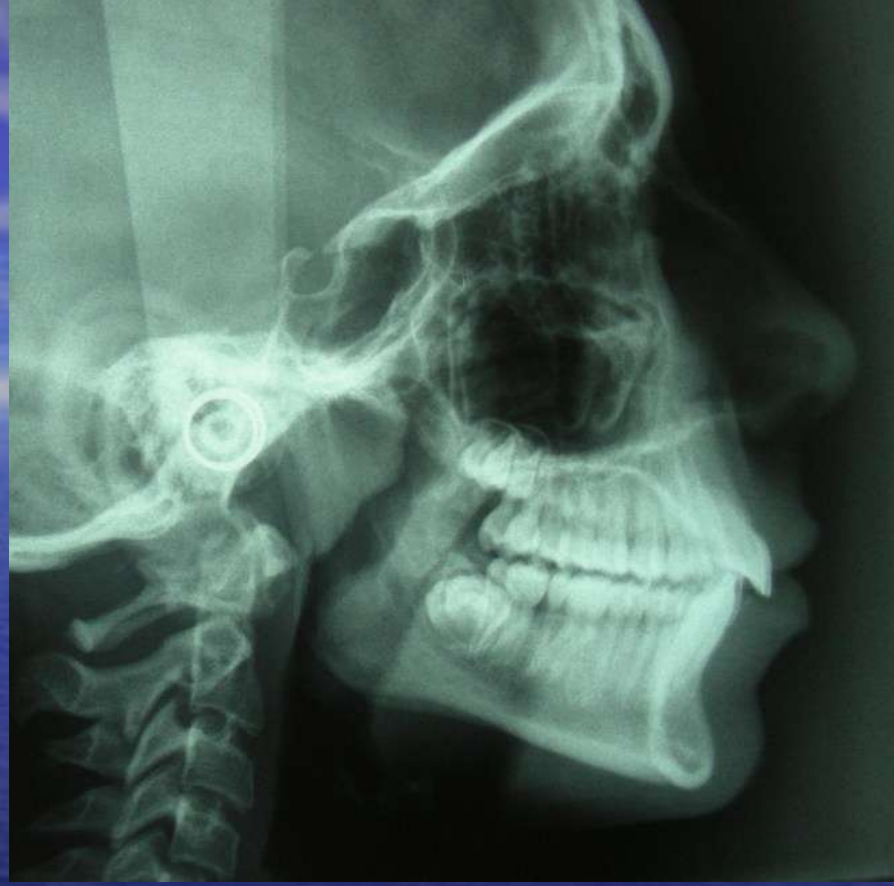
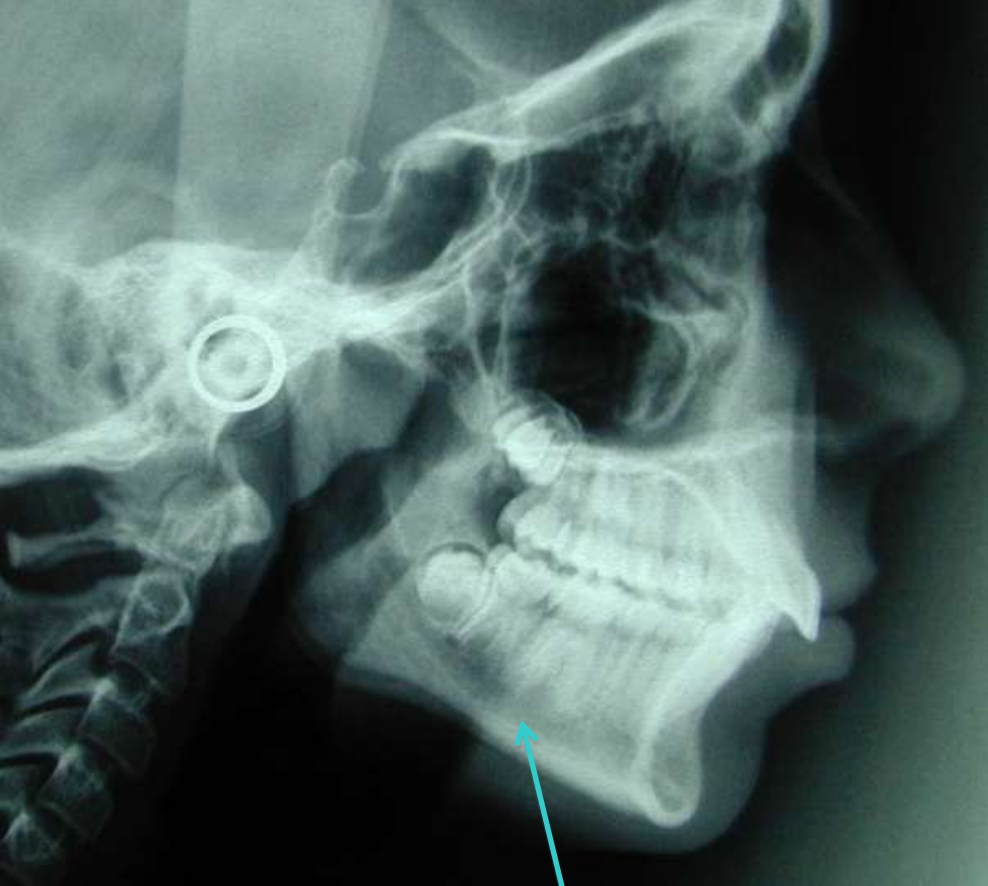
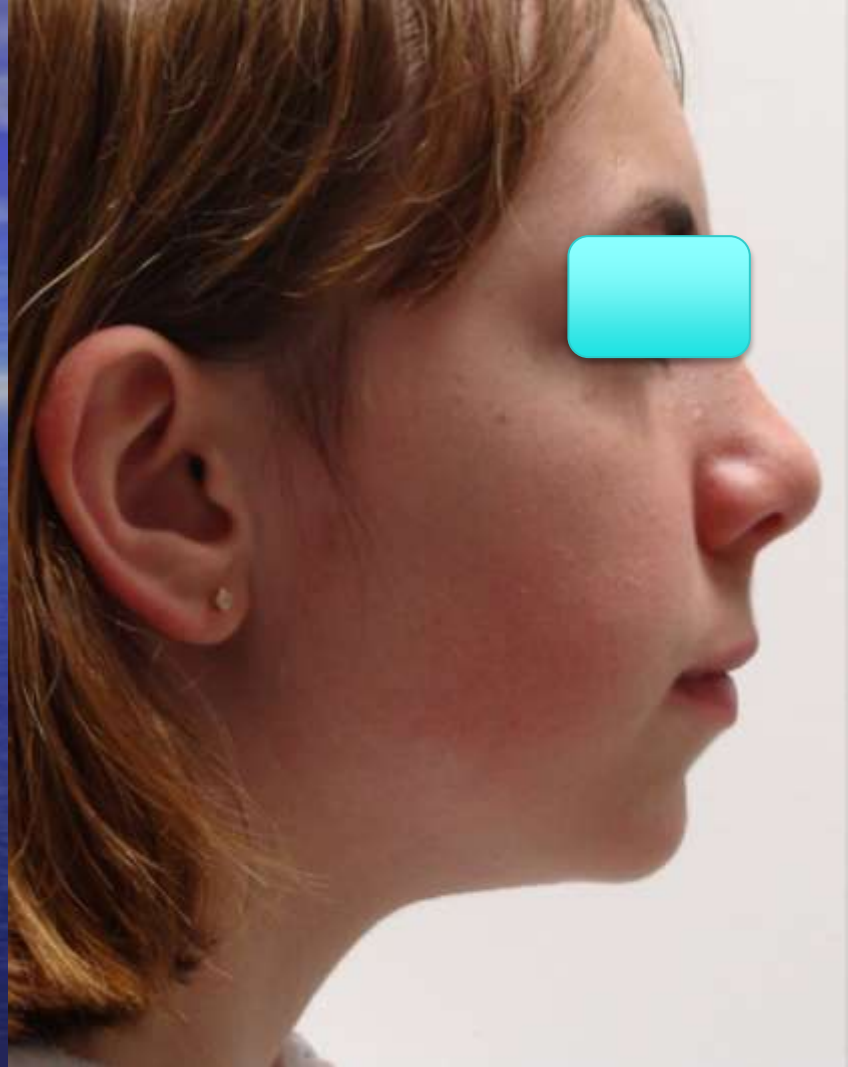



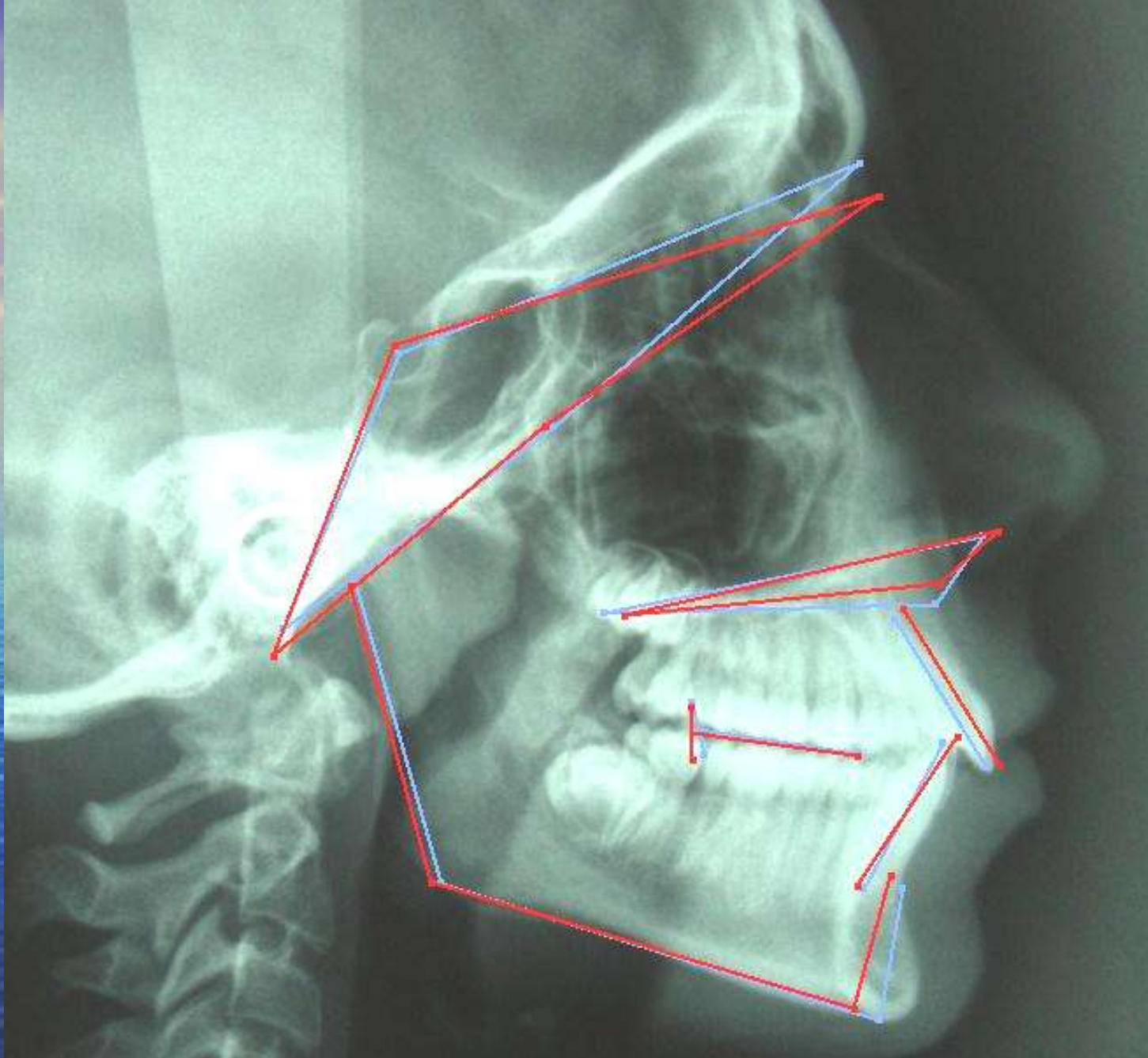









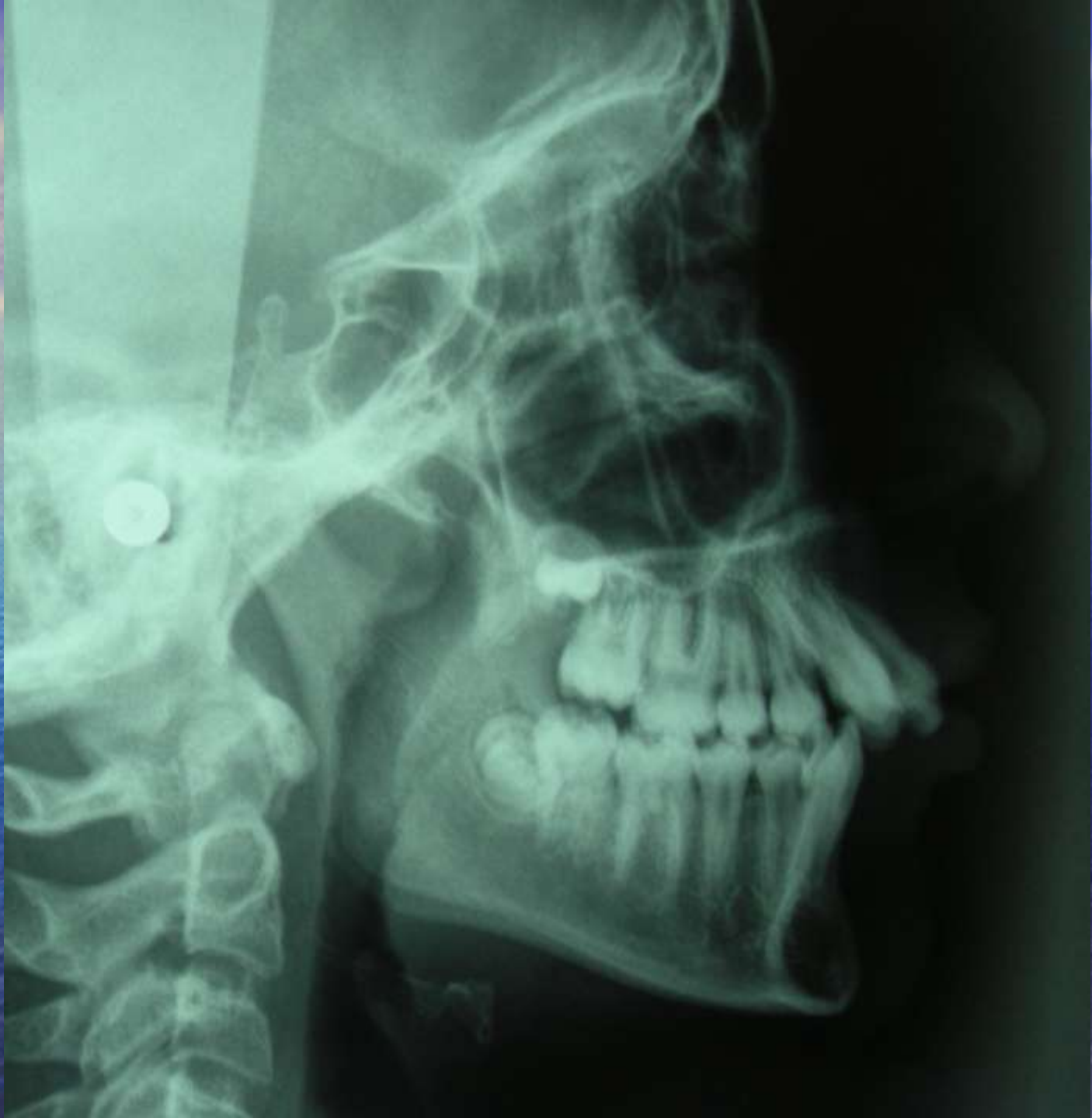


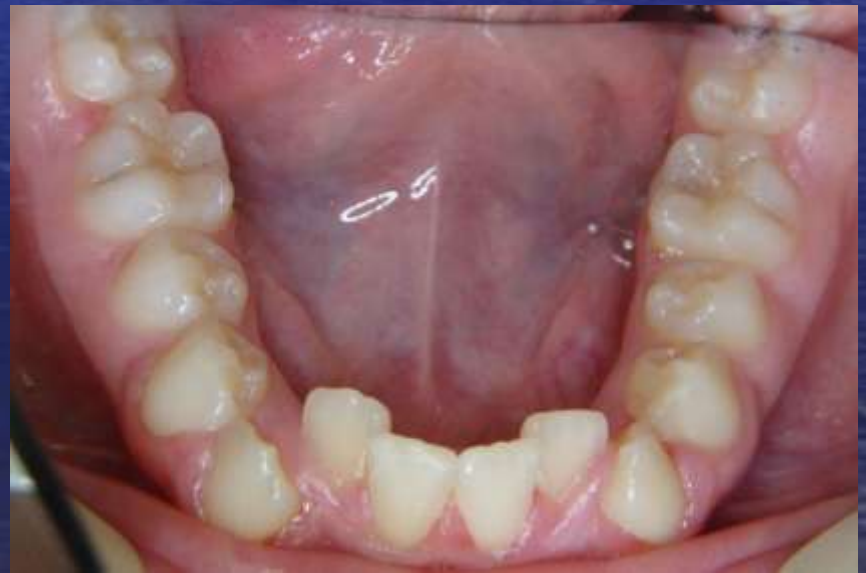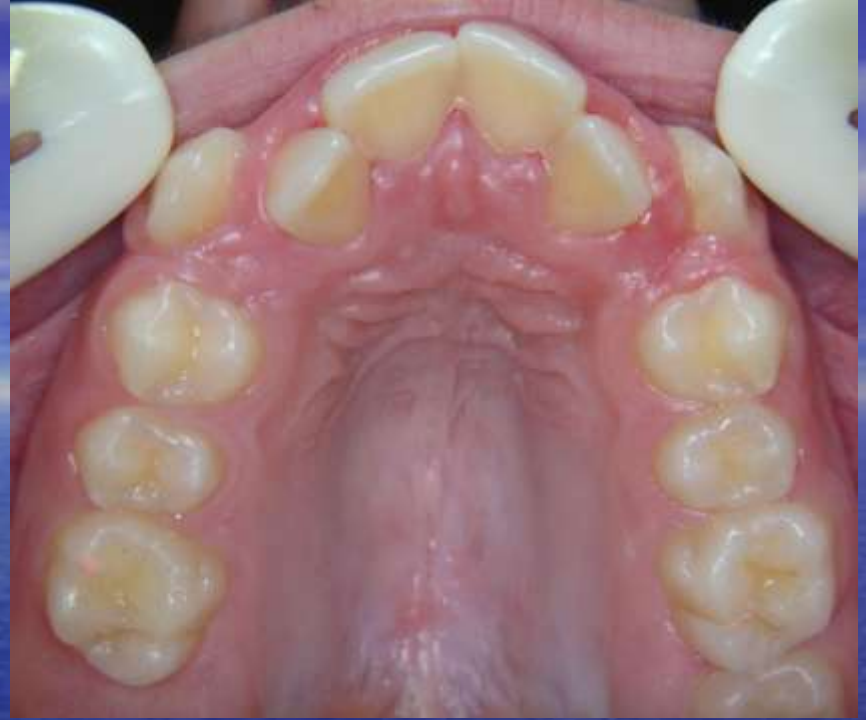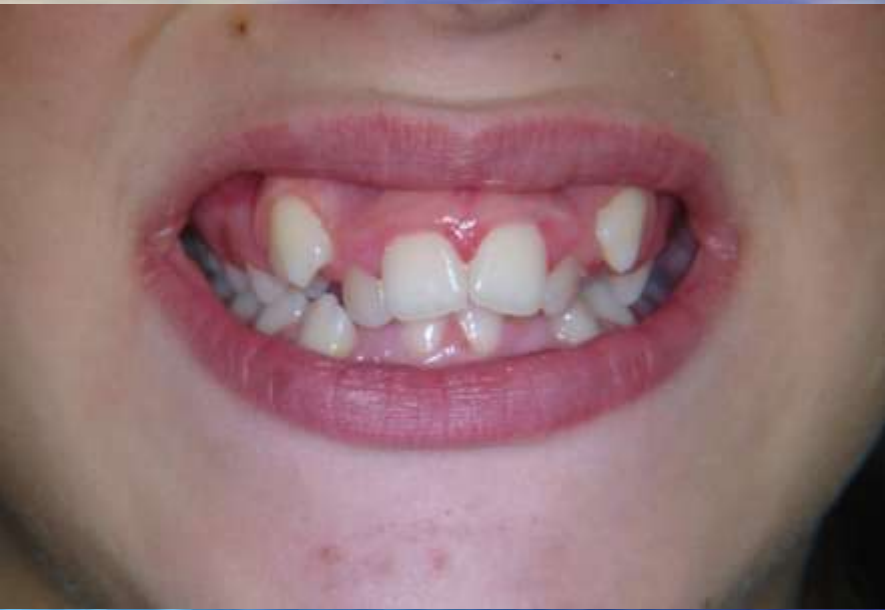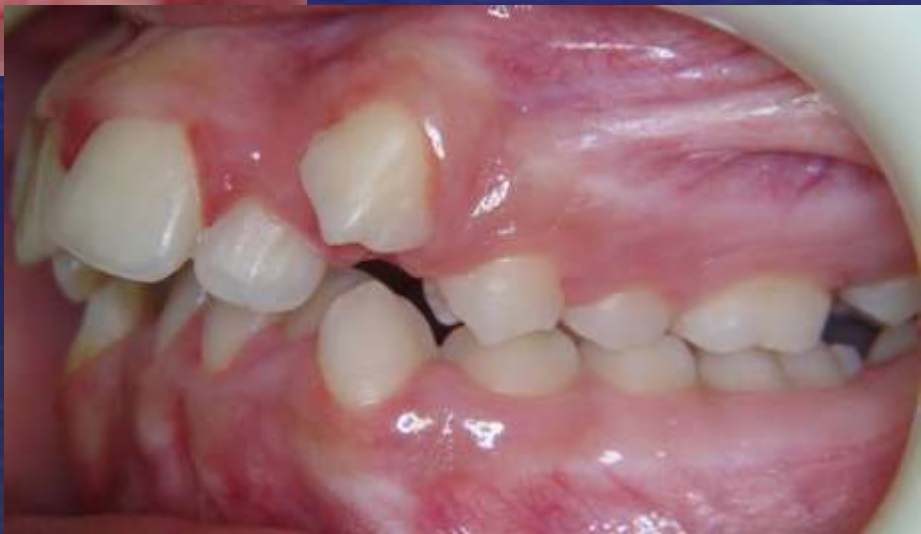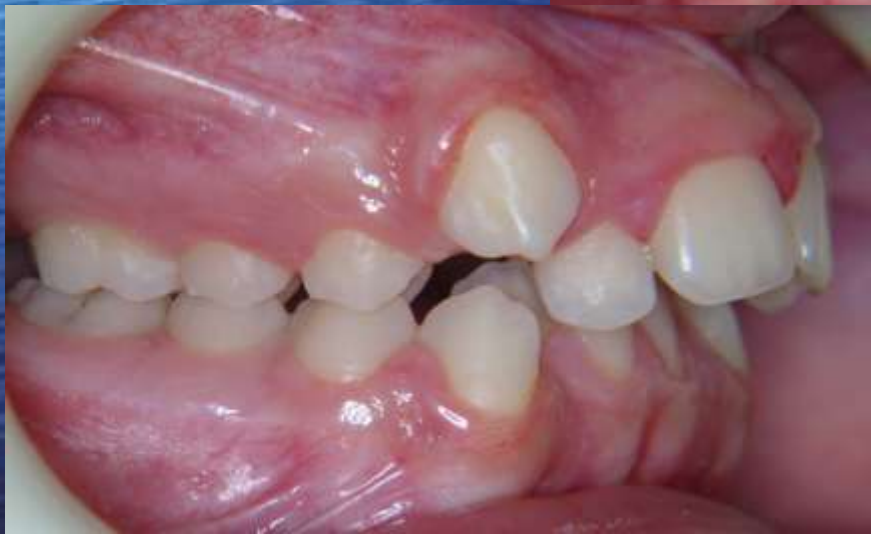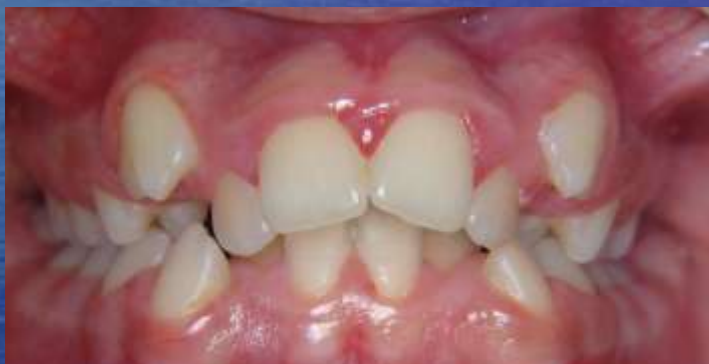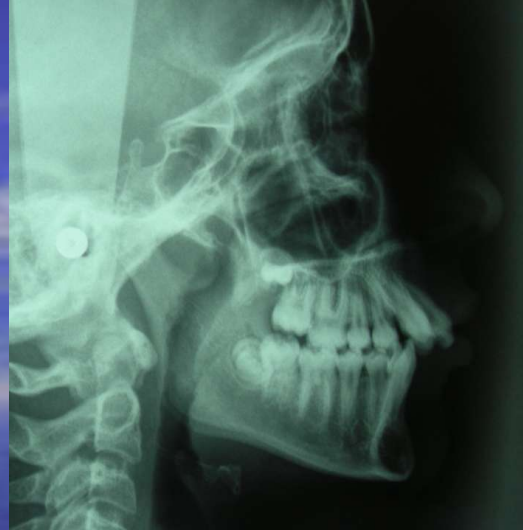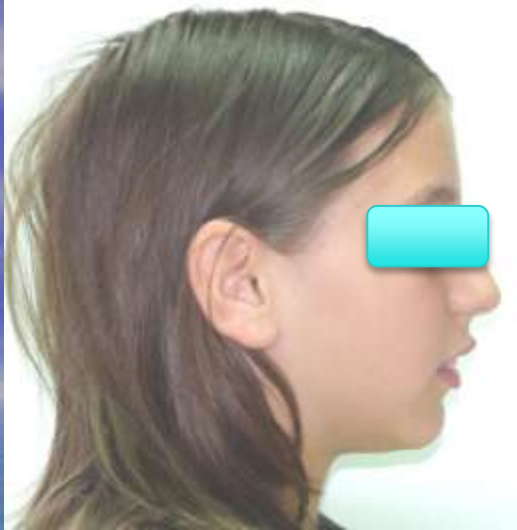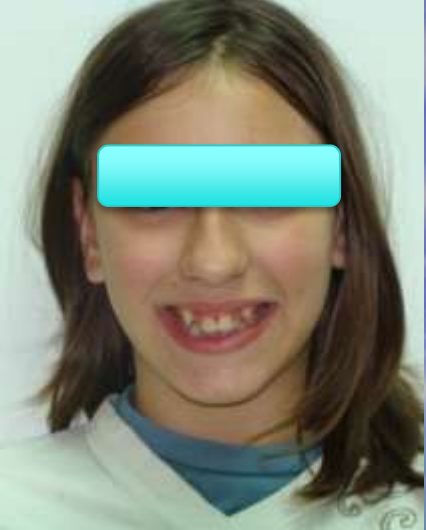Procuste : Avant-Apres PUL

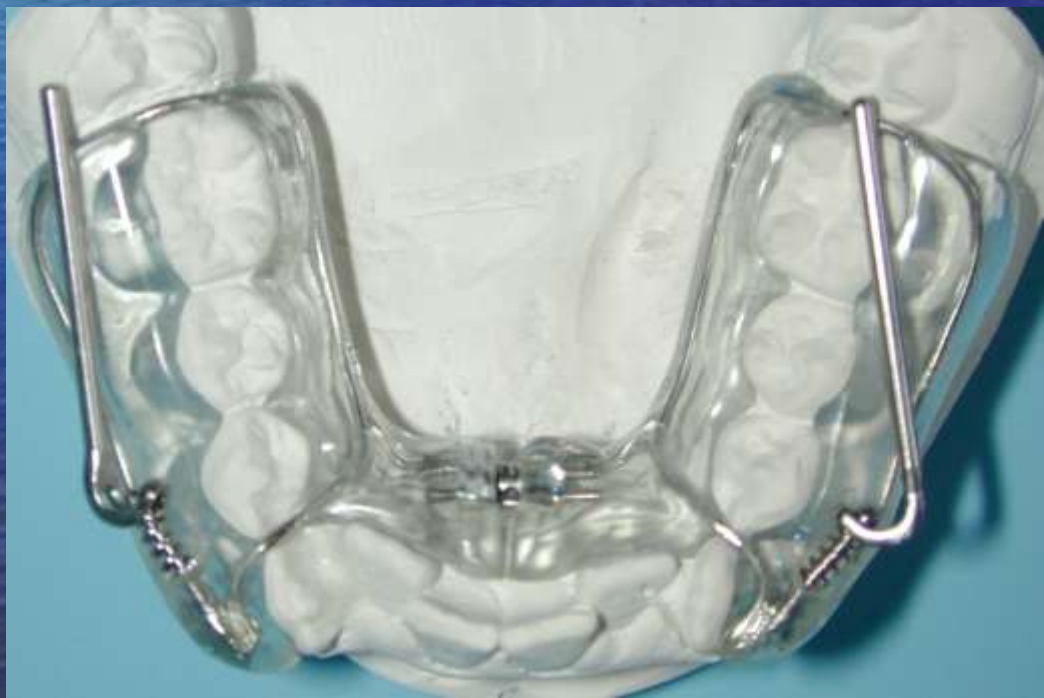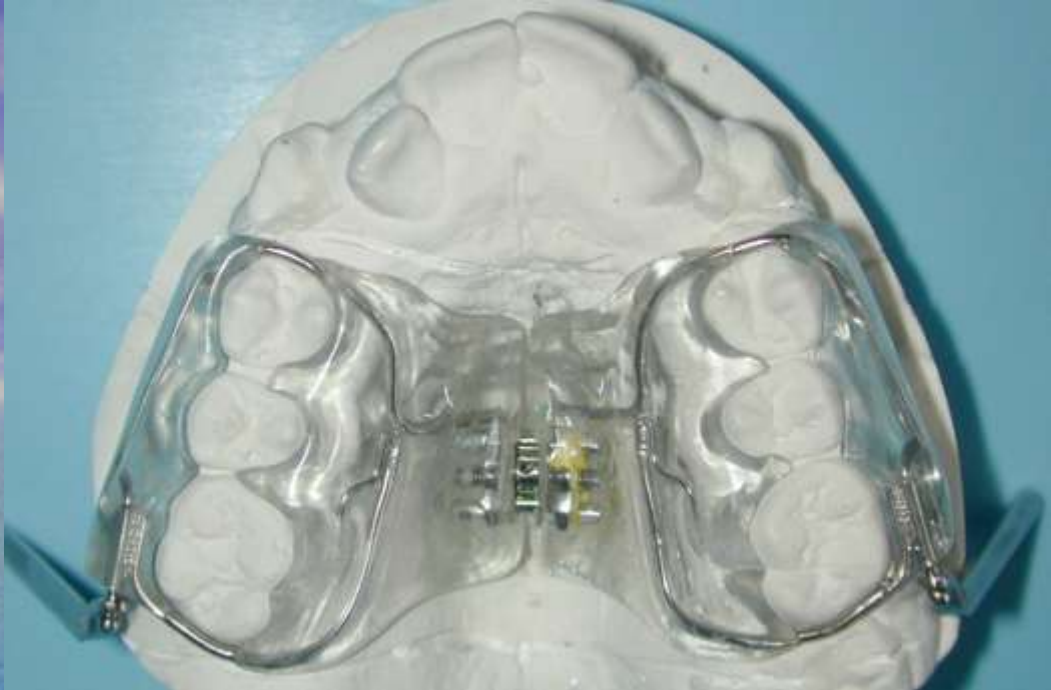PUL Bi-expansion

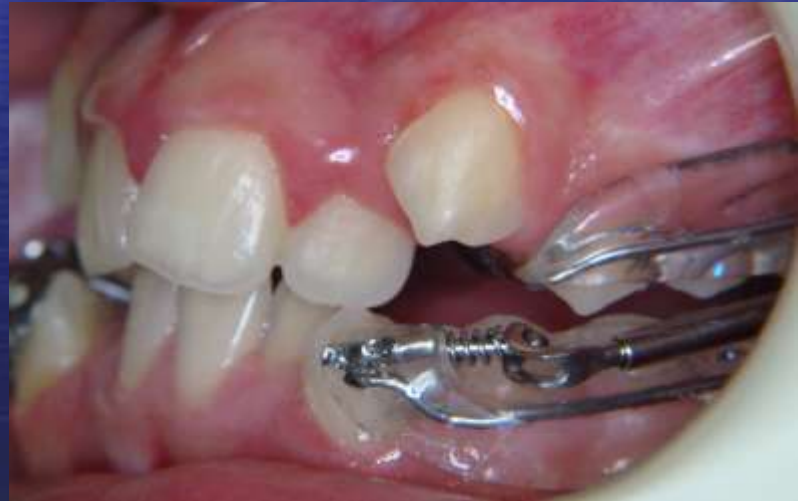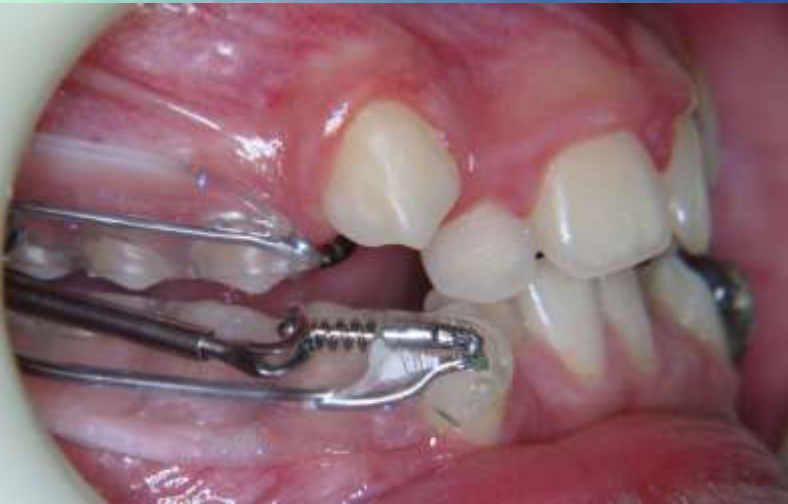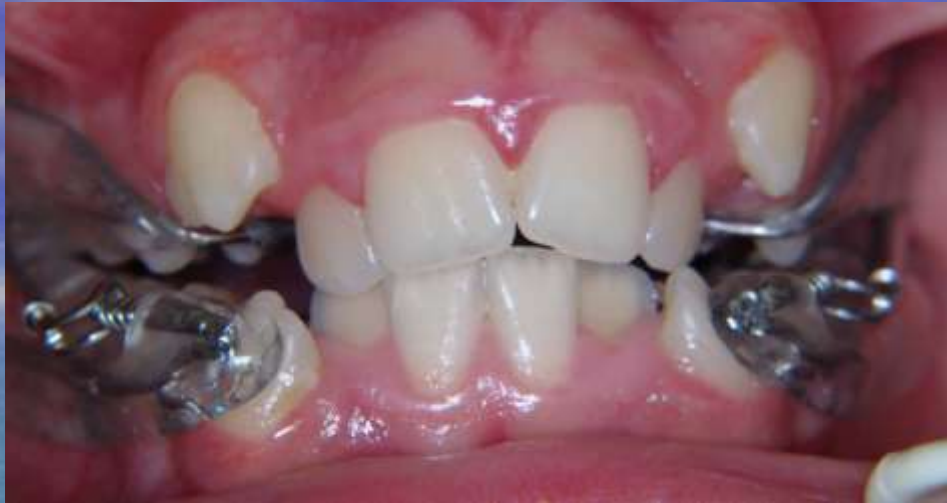Amandine Bour.

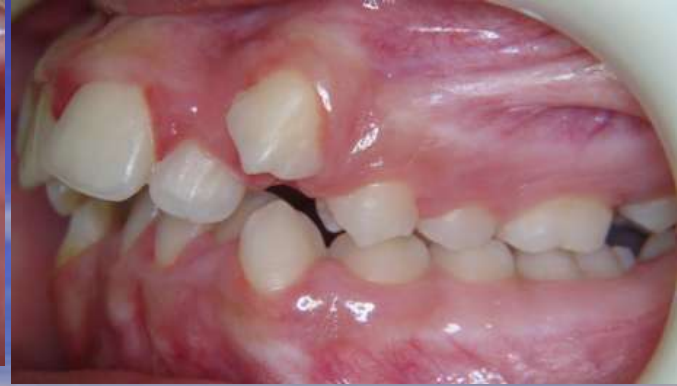
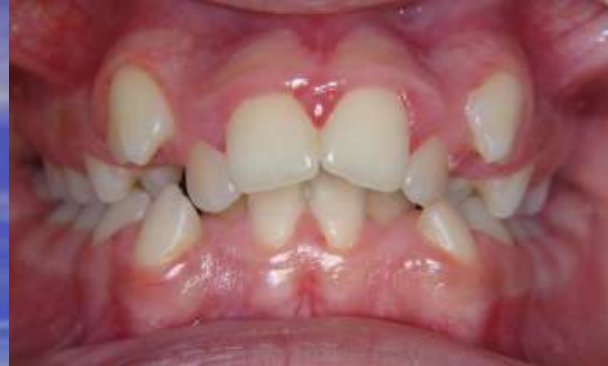
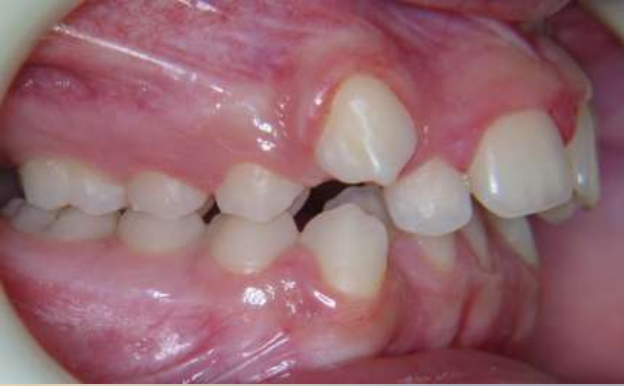




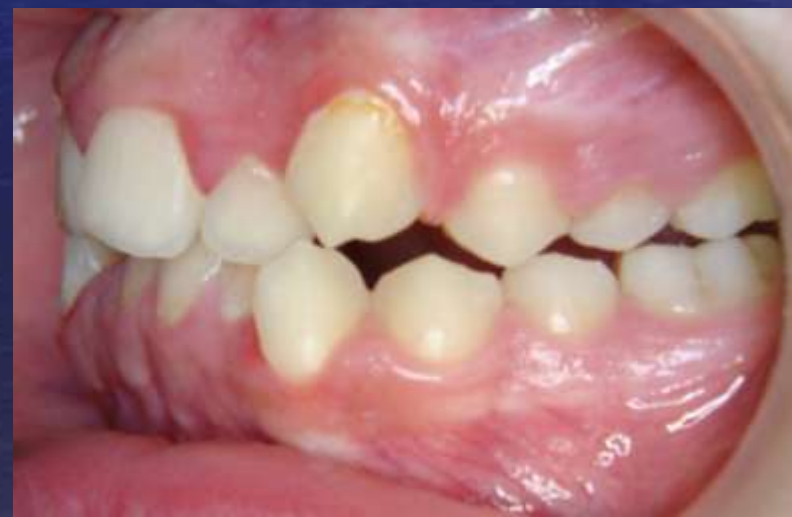
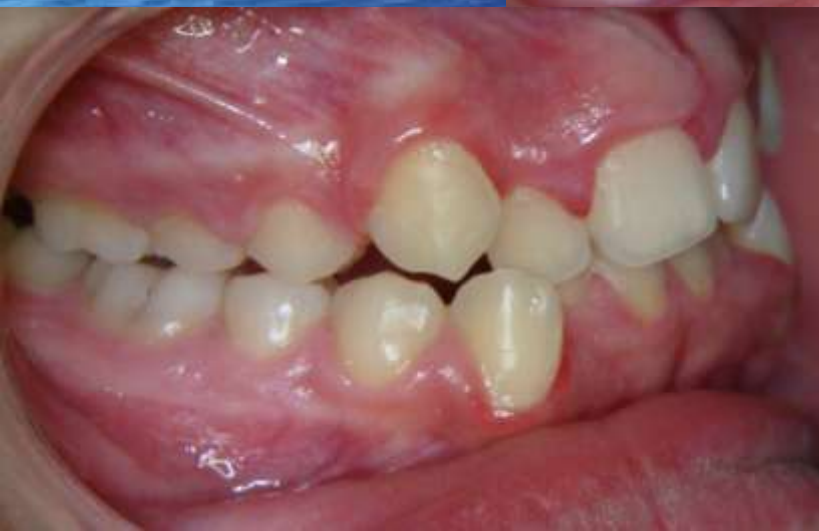
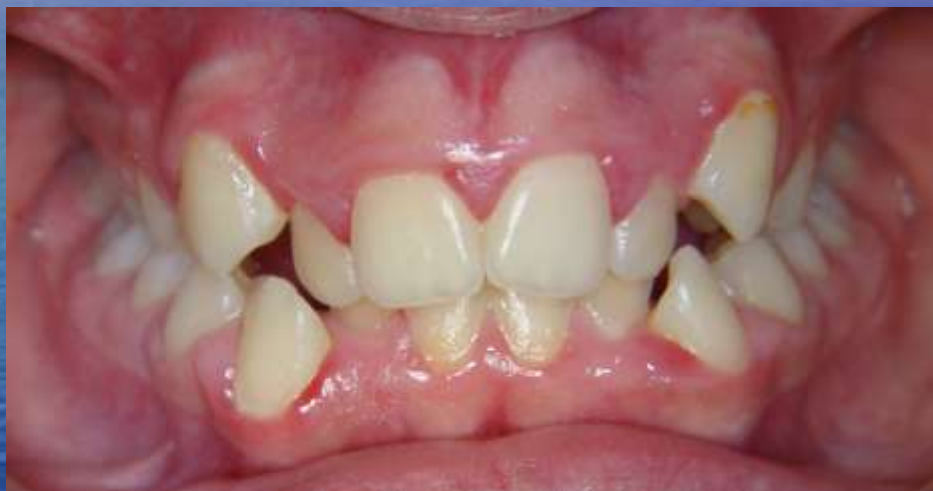


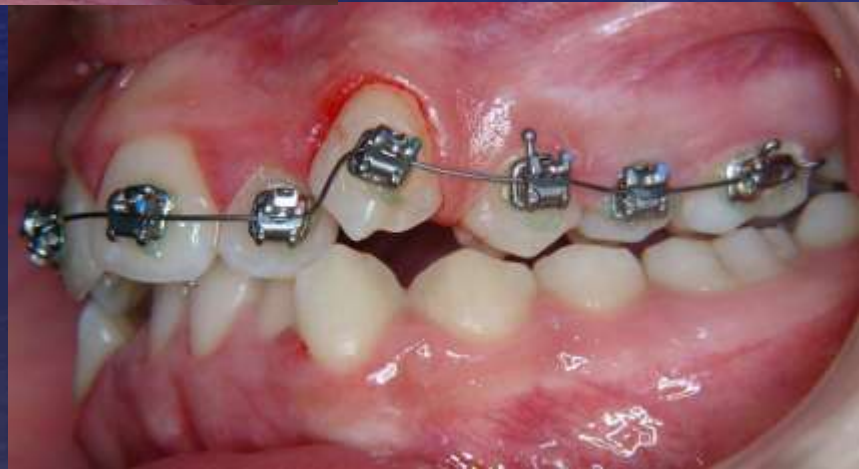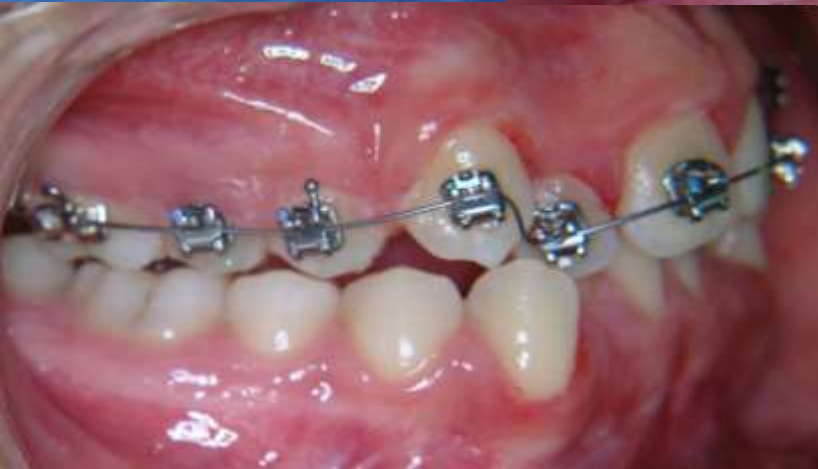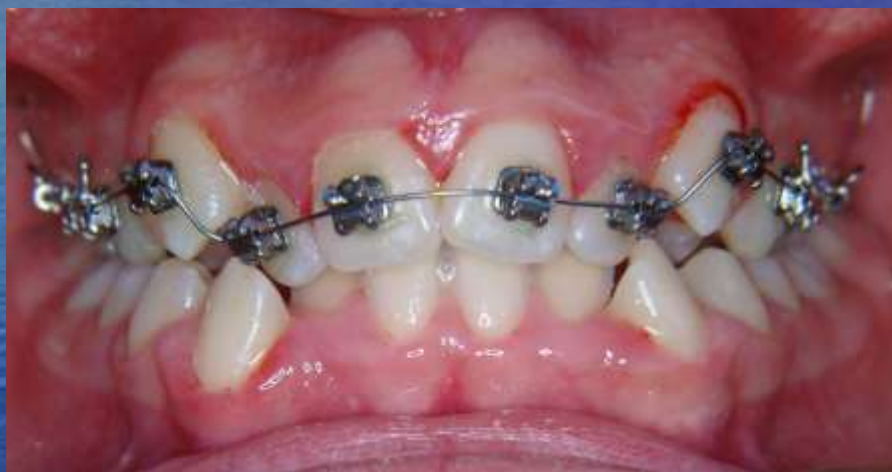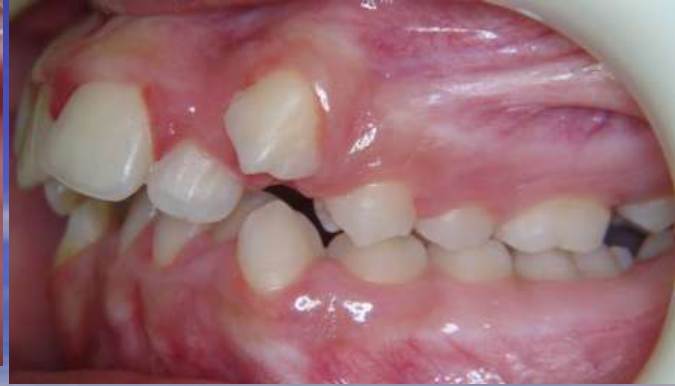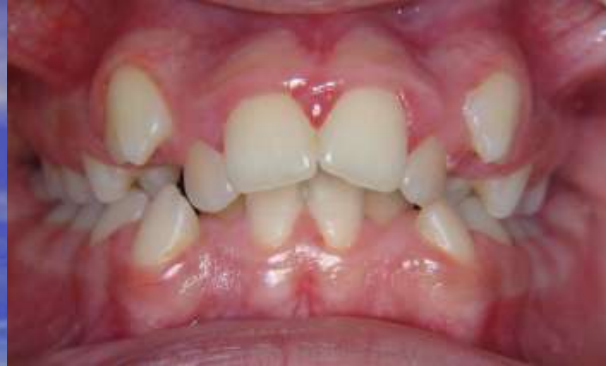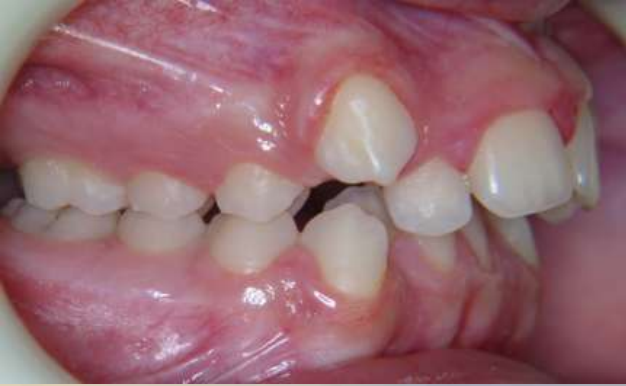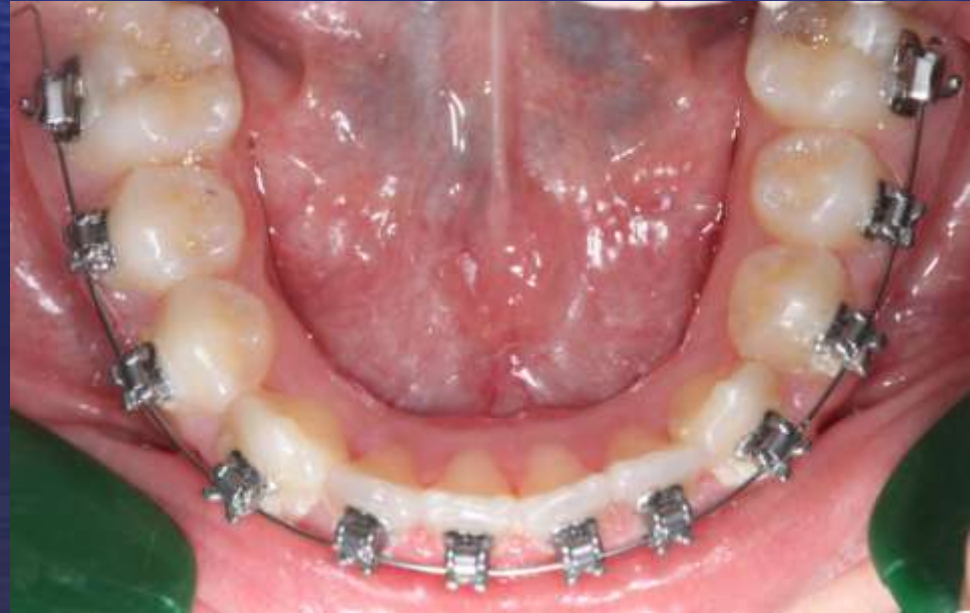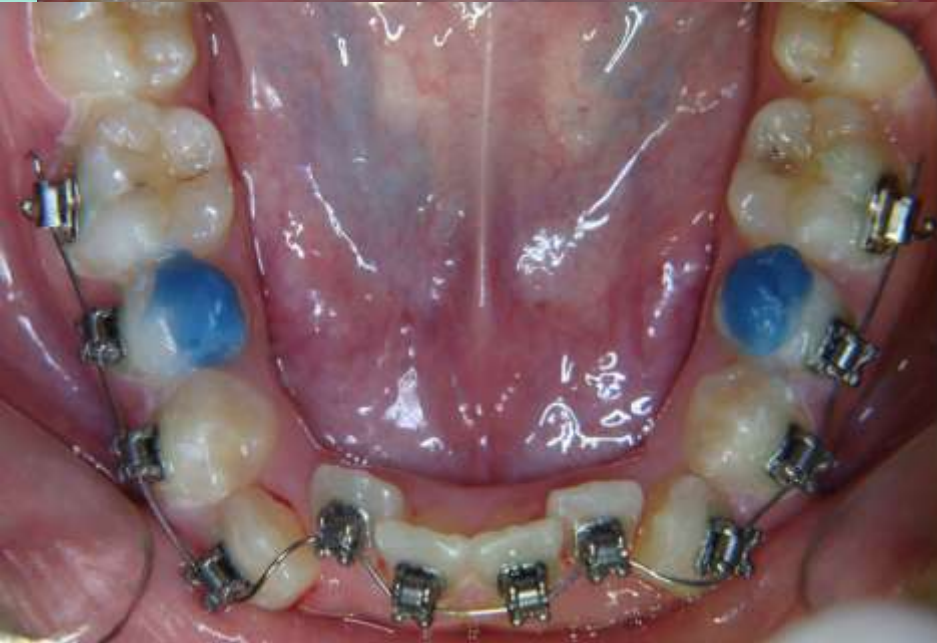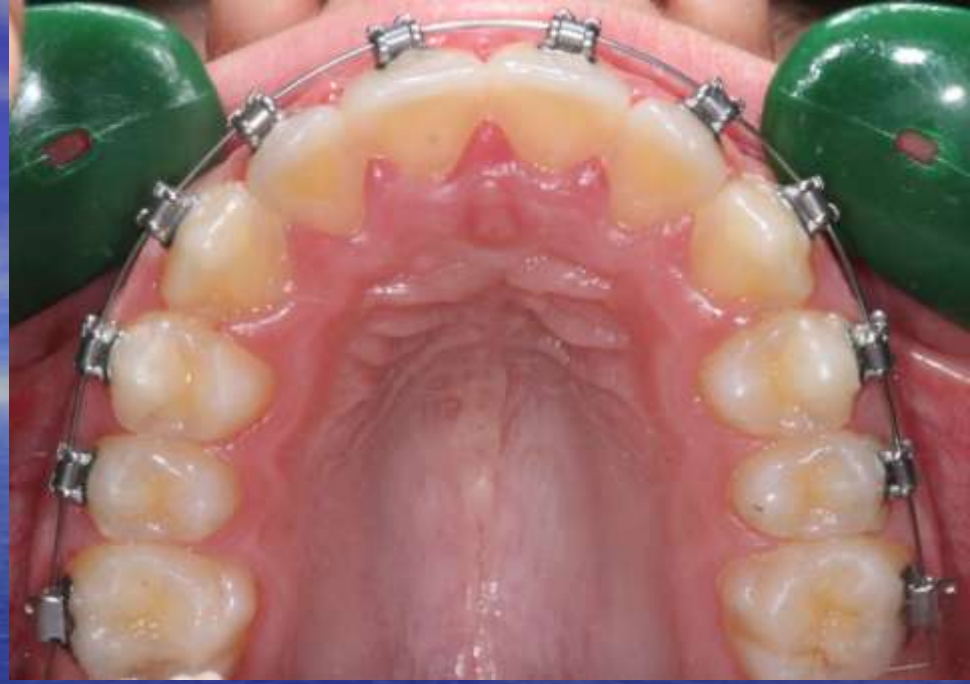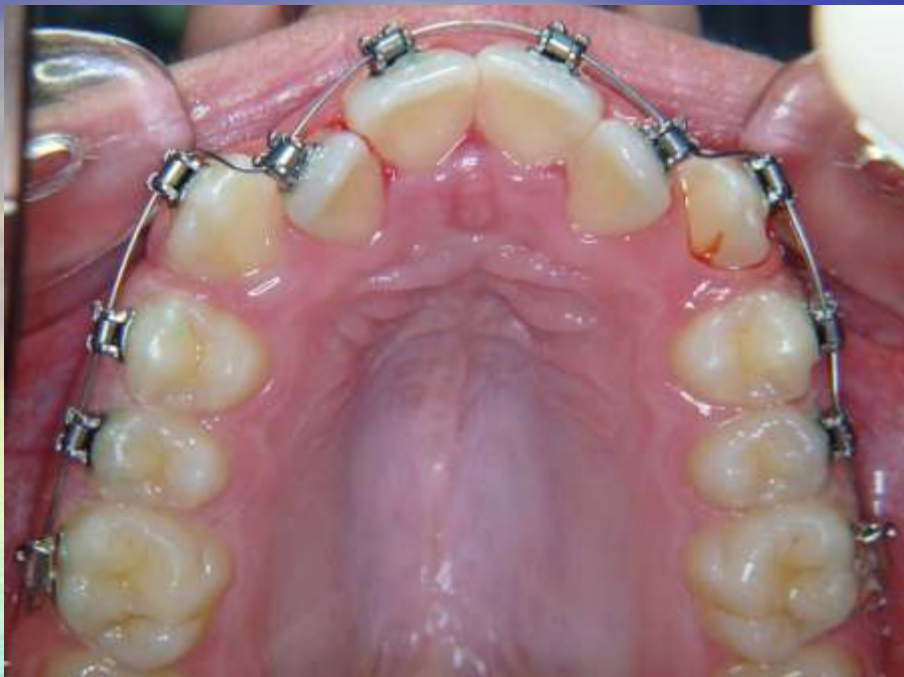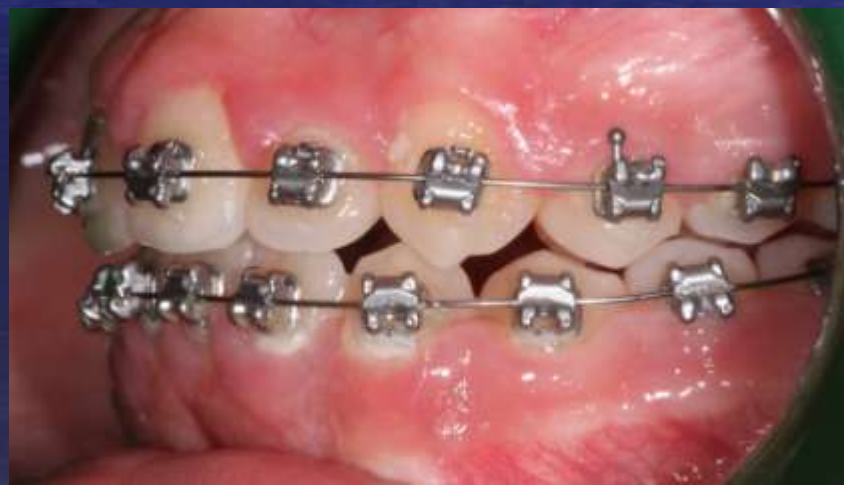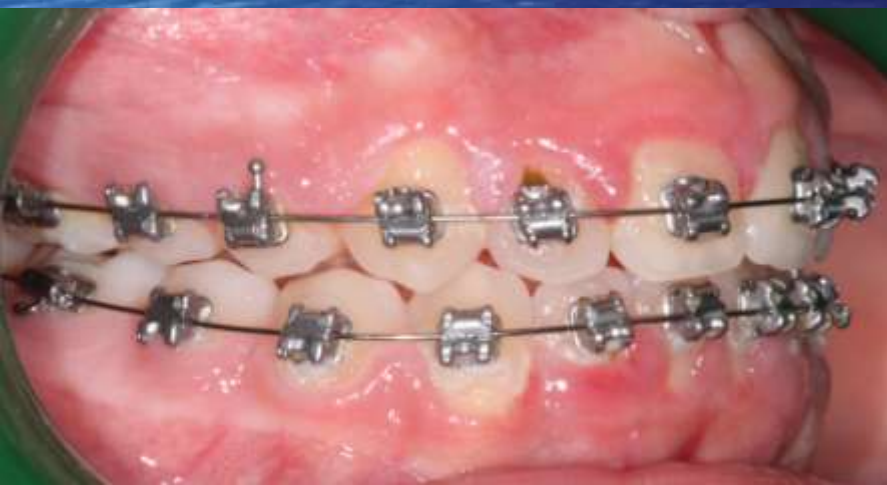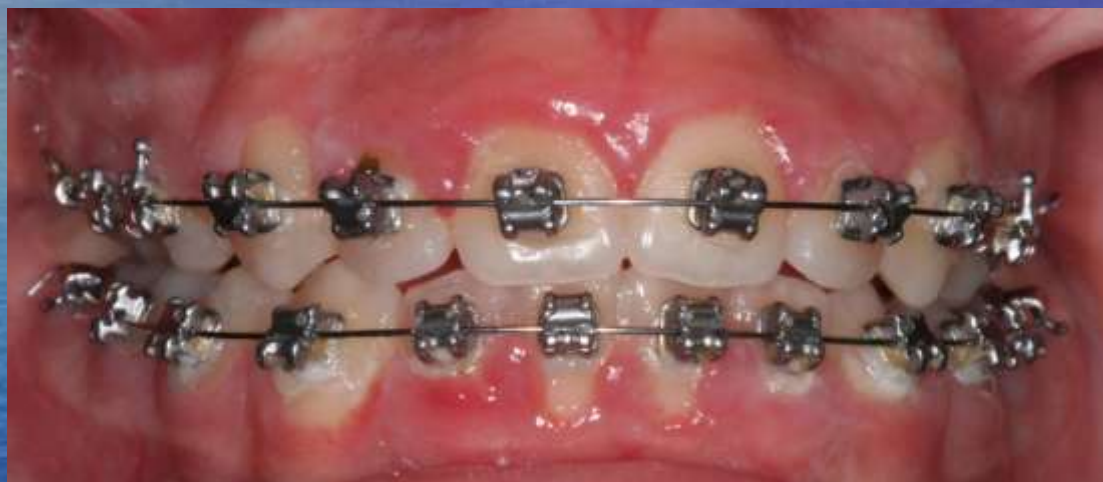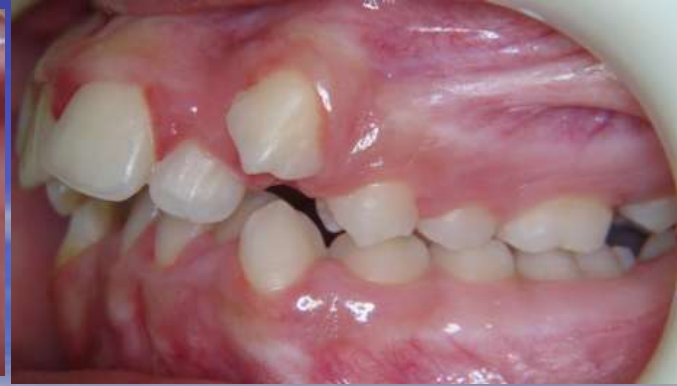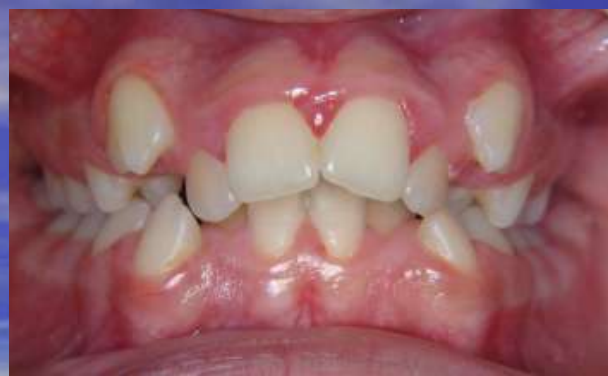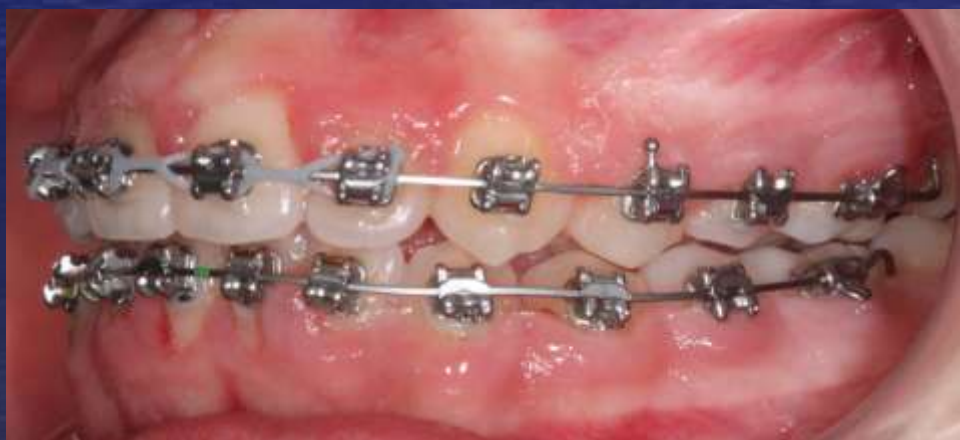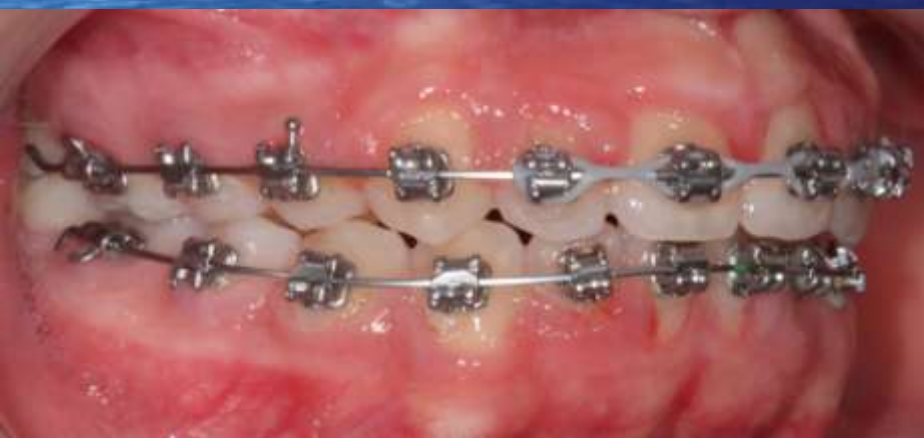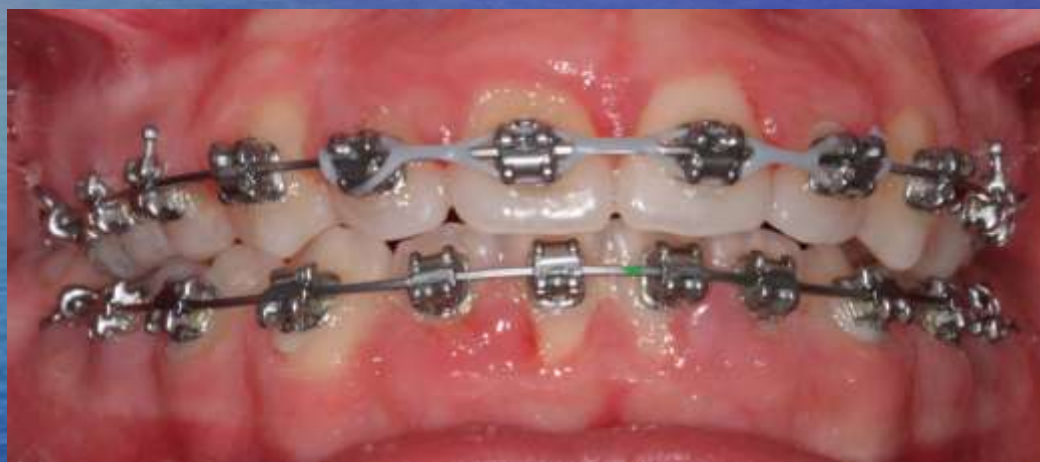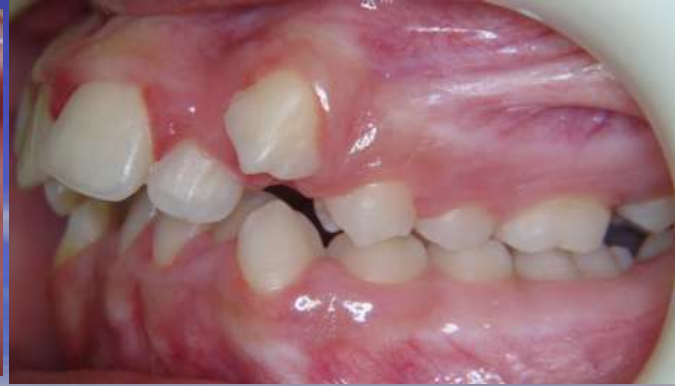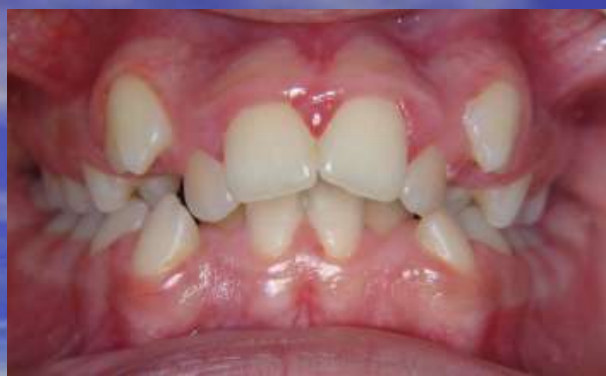PUL 9 M.











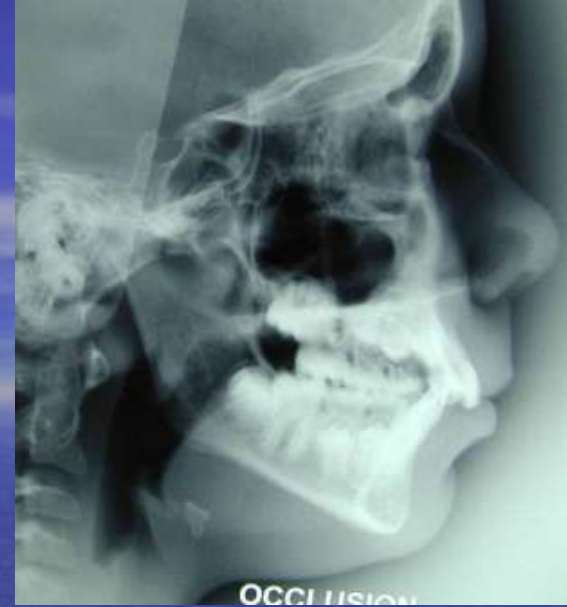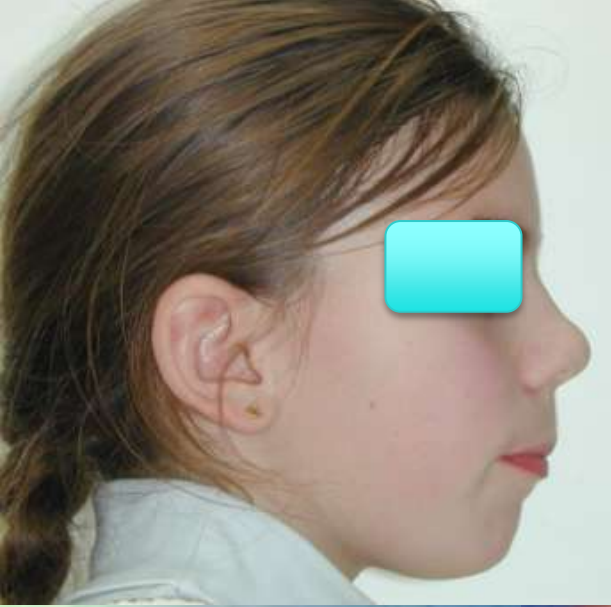




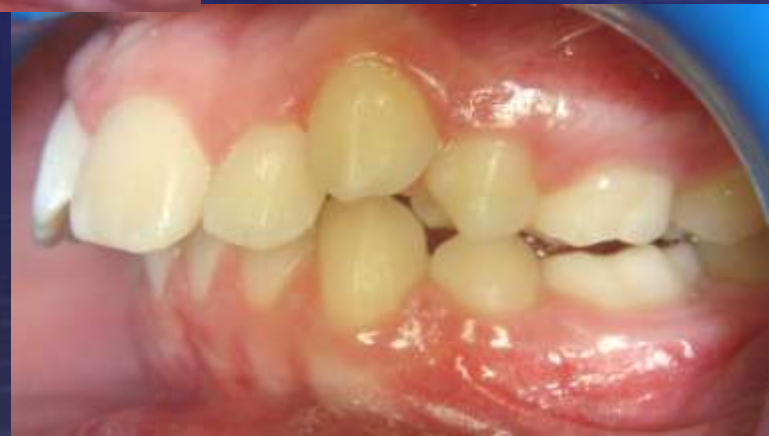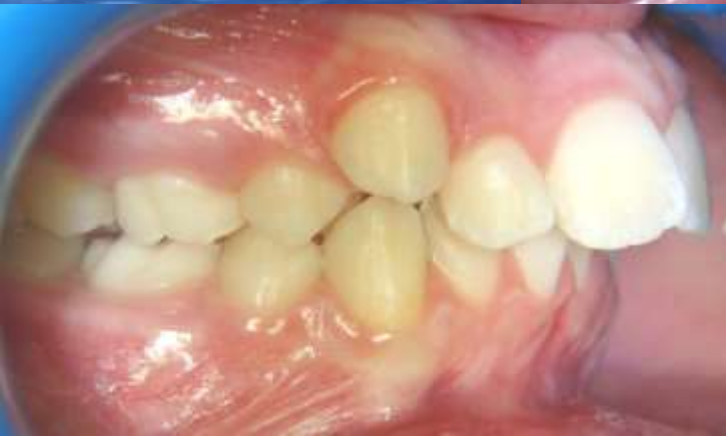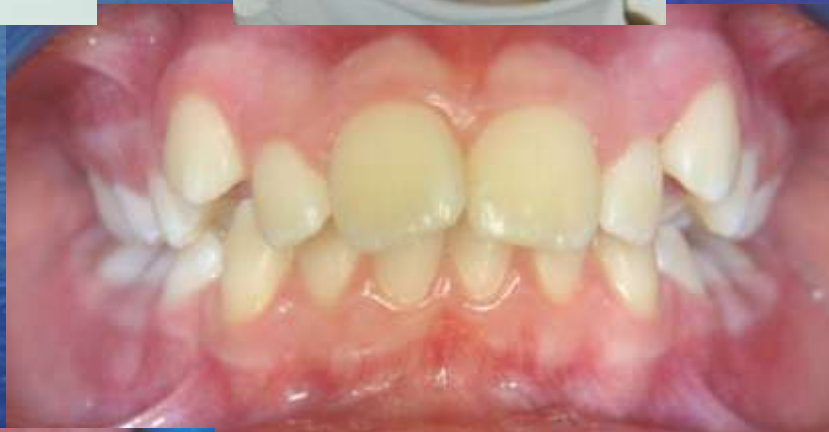PUL

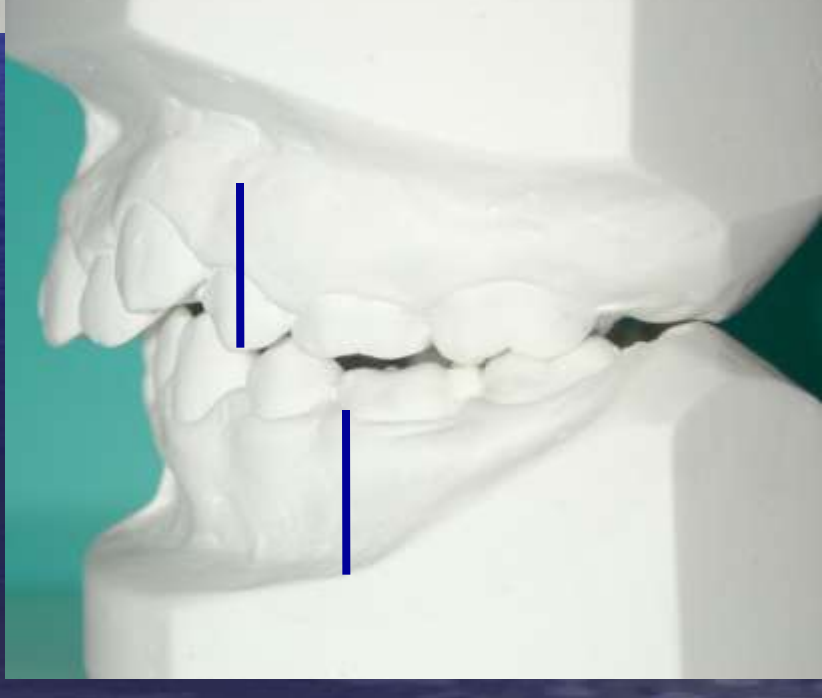
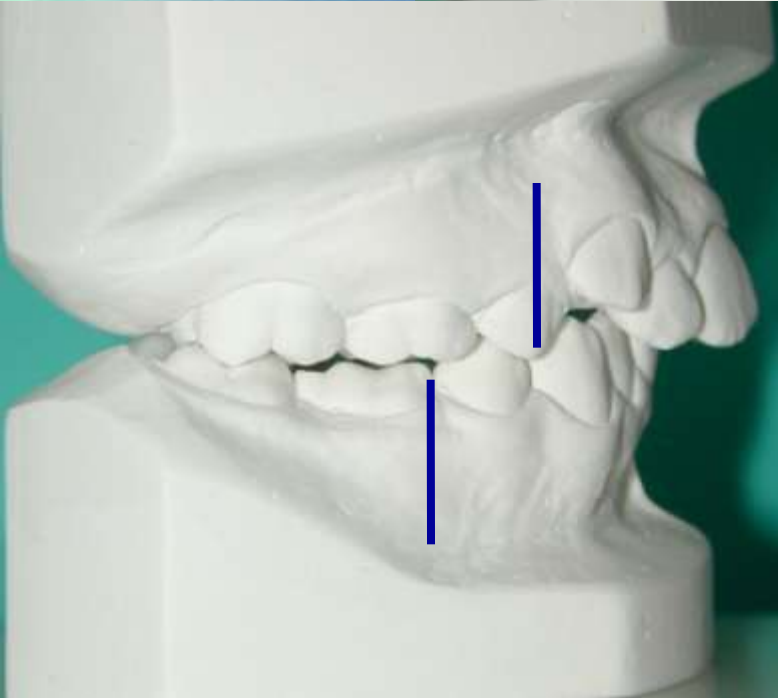
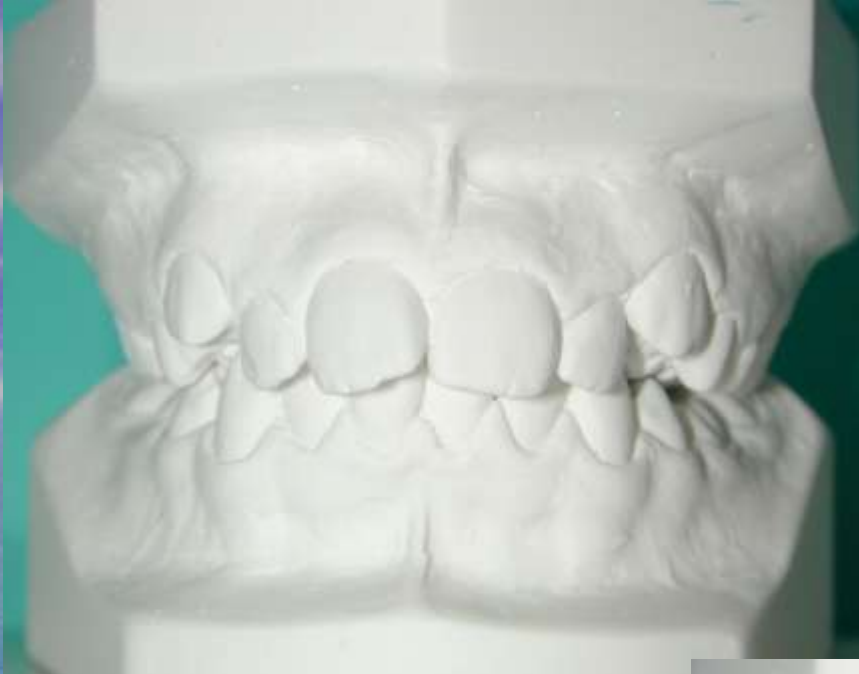CLASSE II ++ hyperdivergente

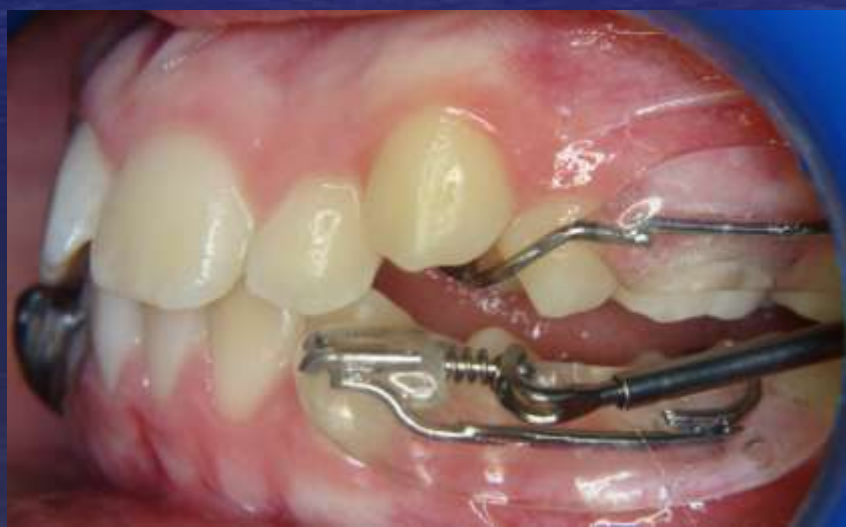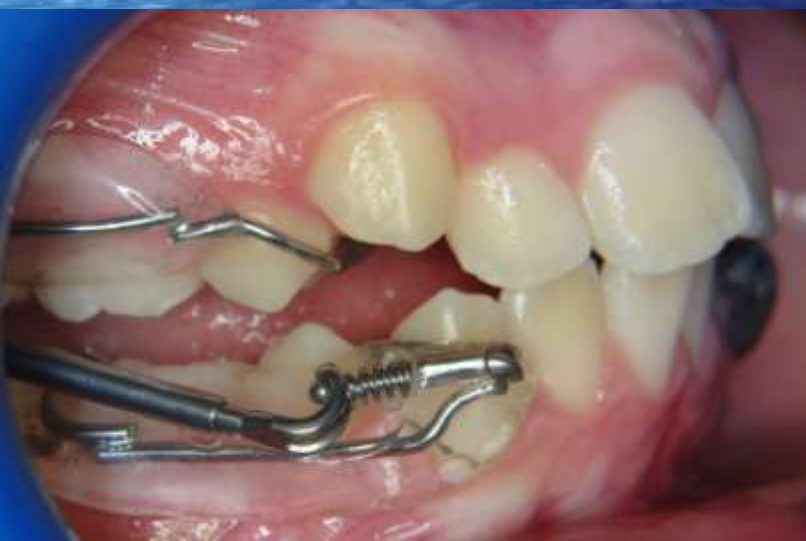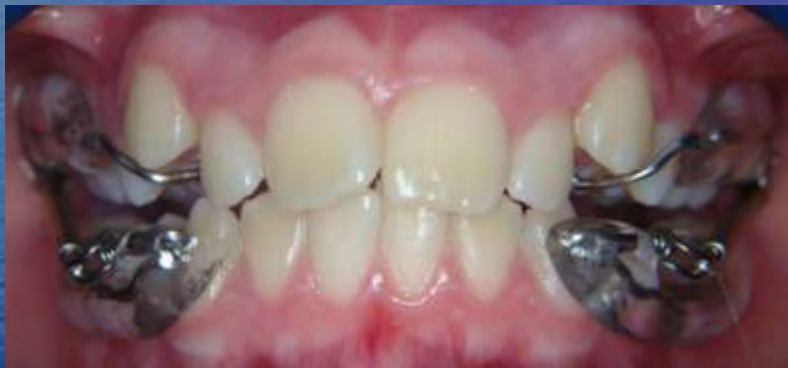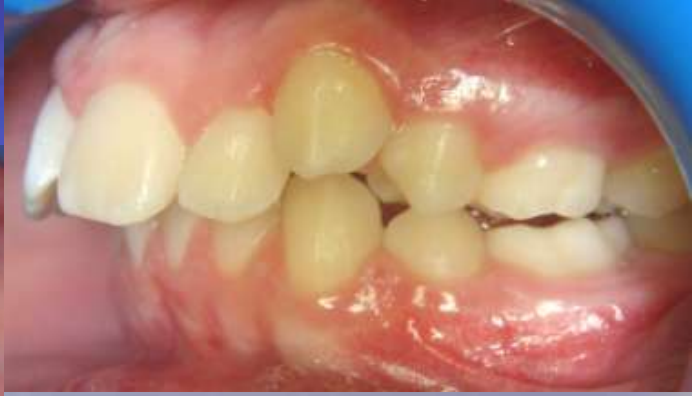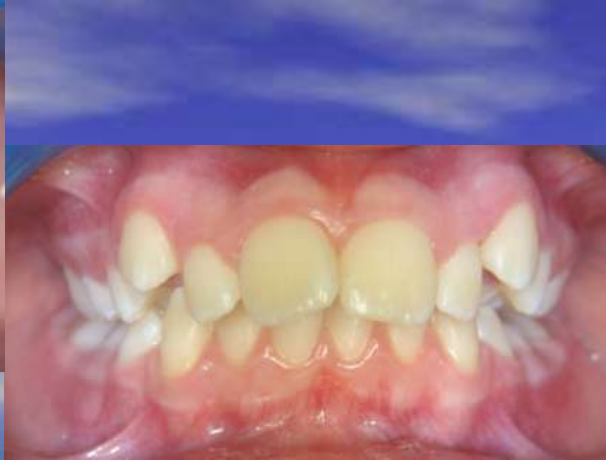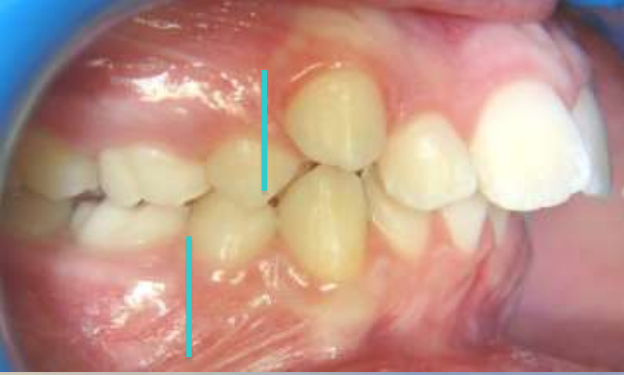L'ancrage mandibulaire
Mandibular anchorage

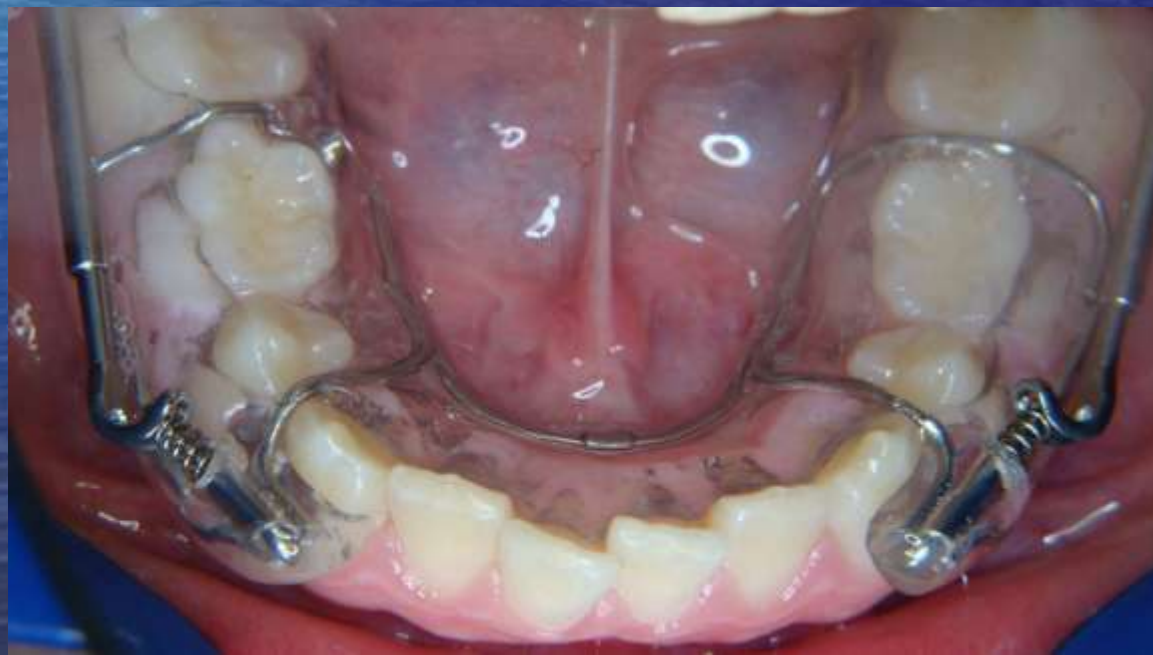
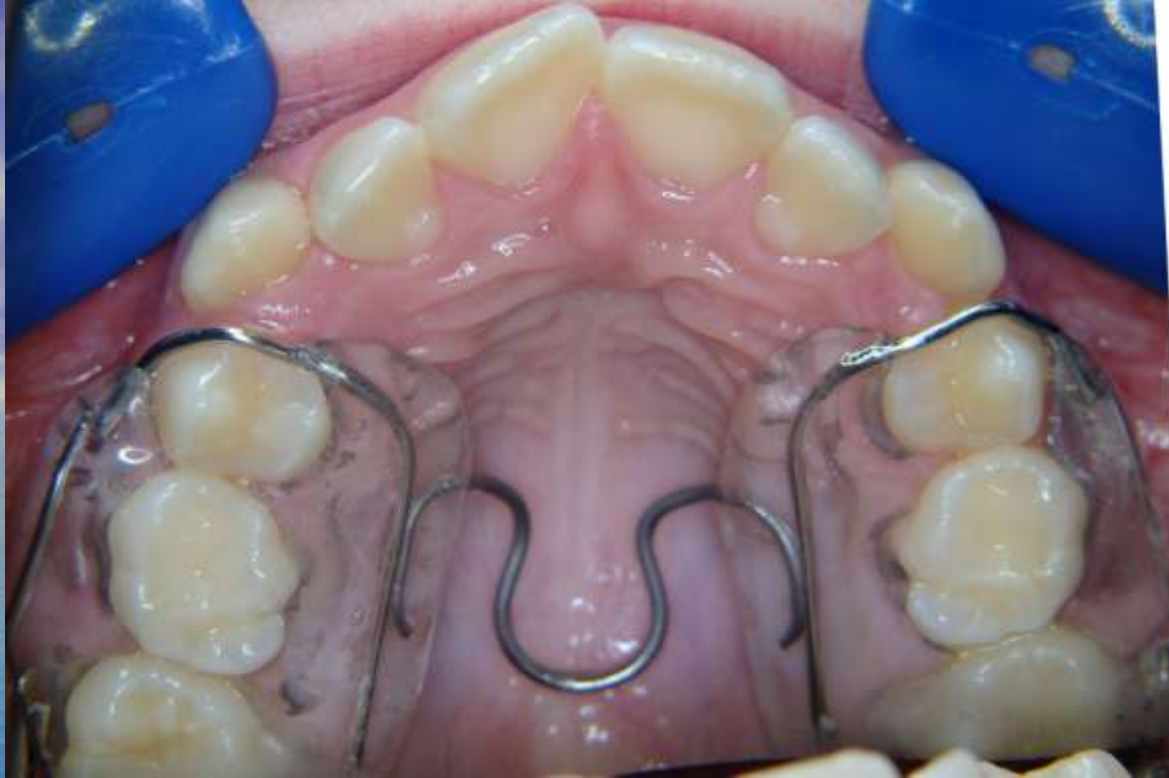
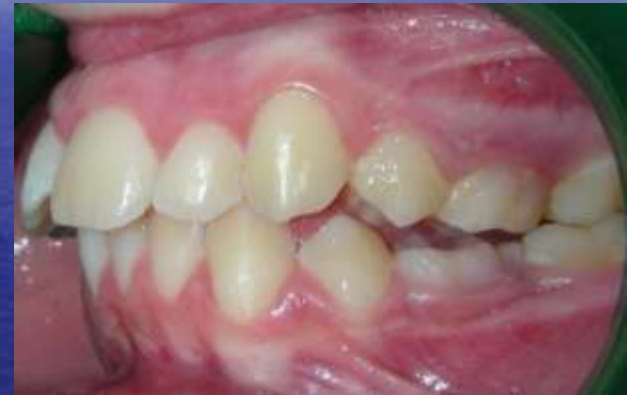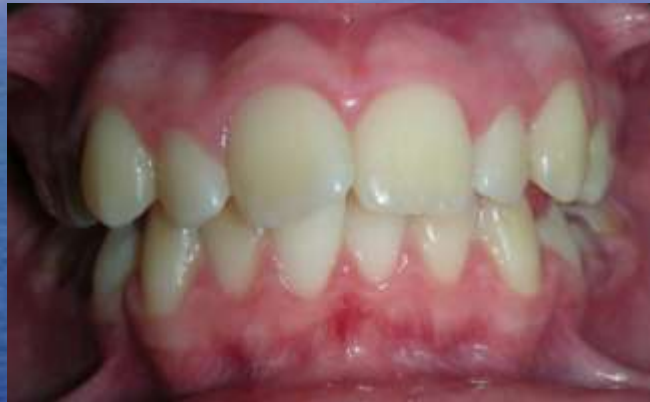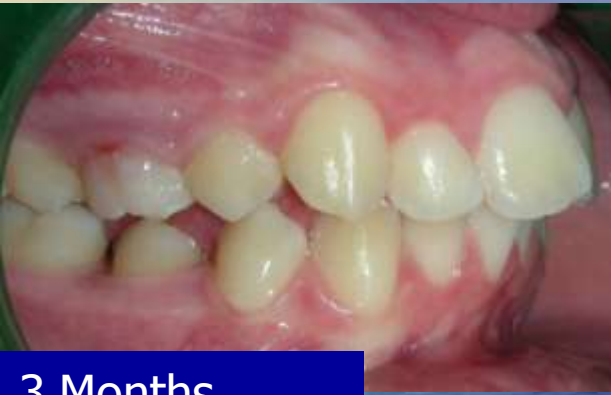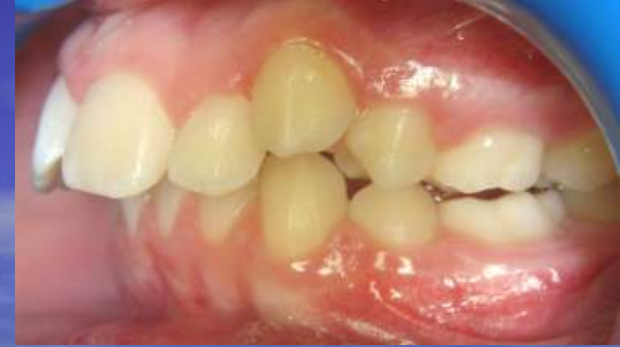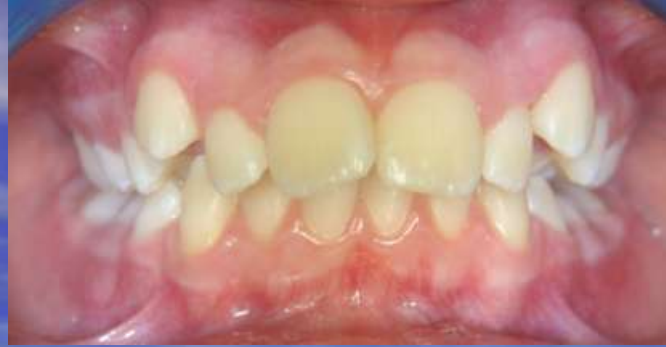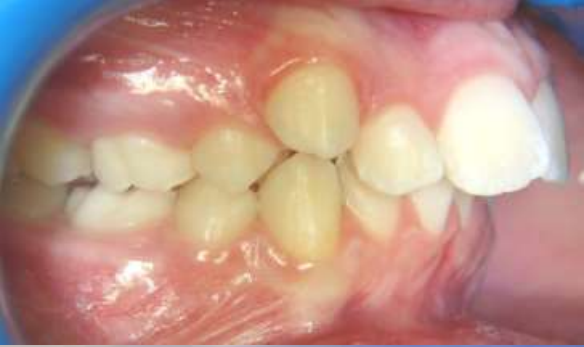Lea Lec.
12 ans





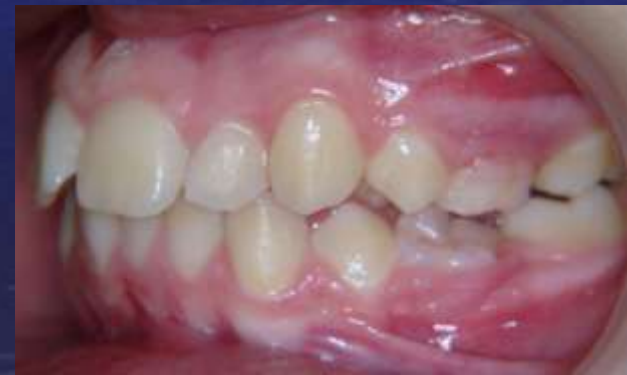
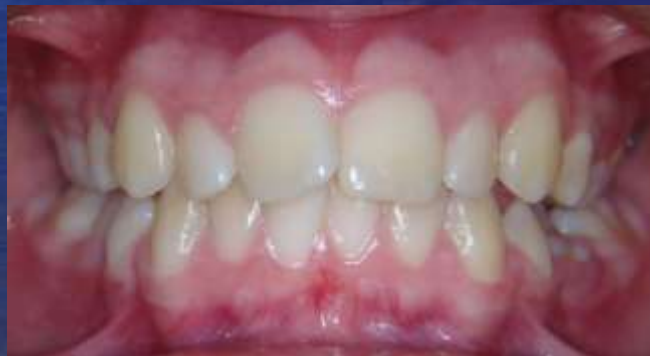
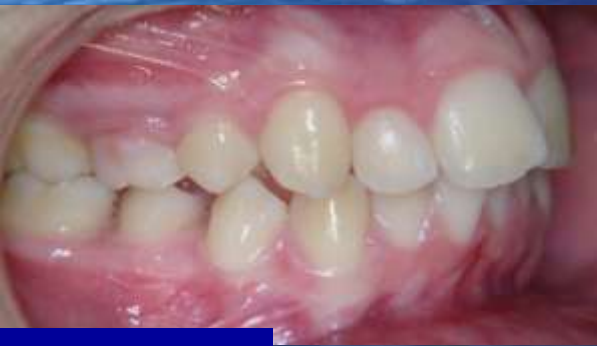

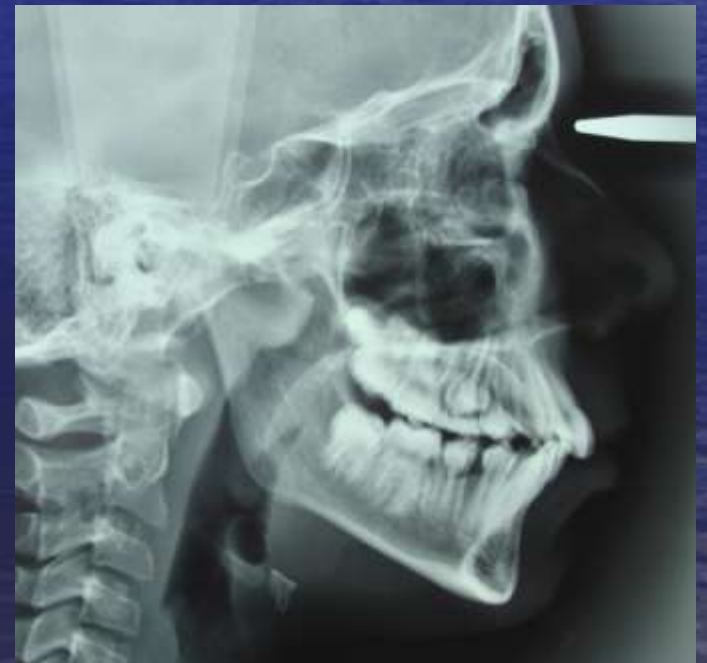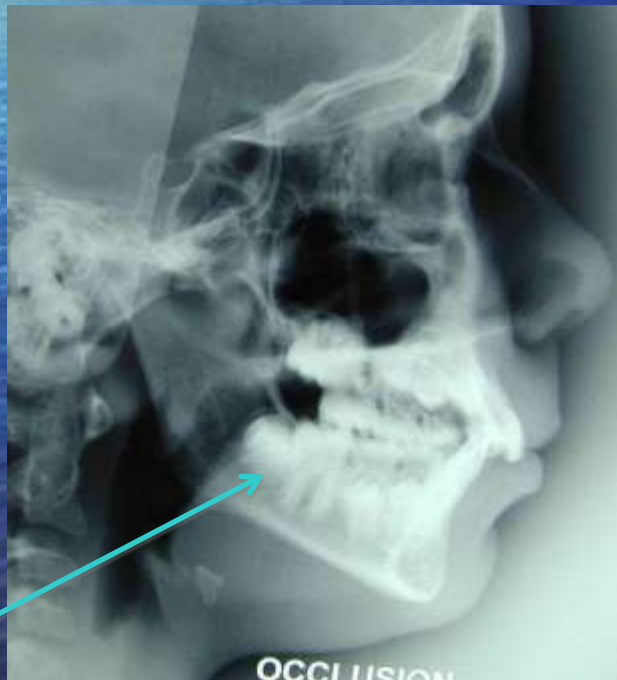



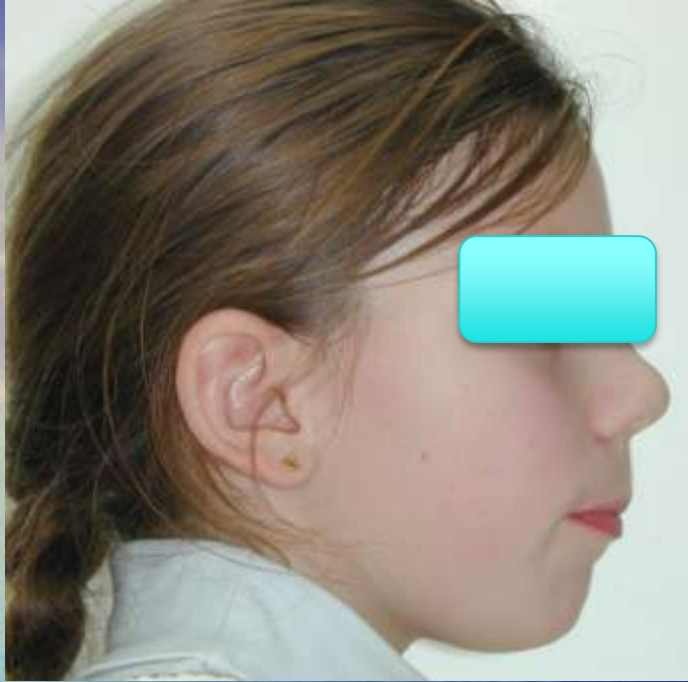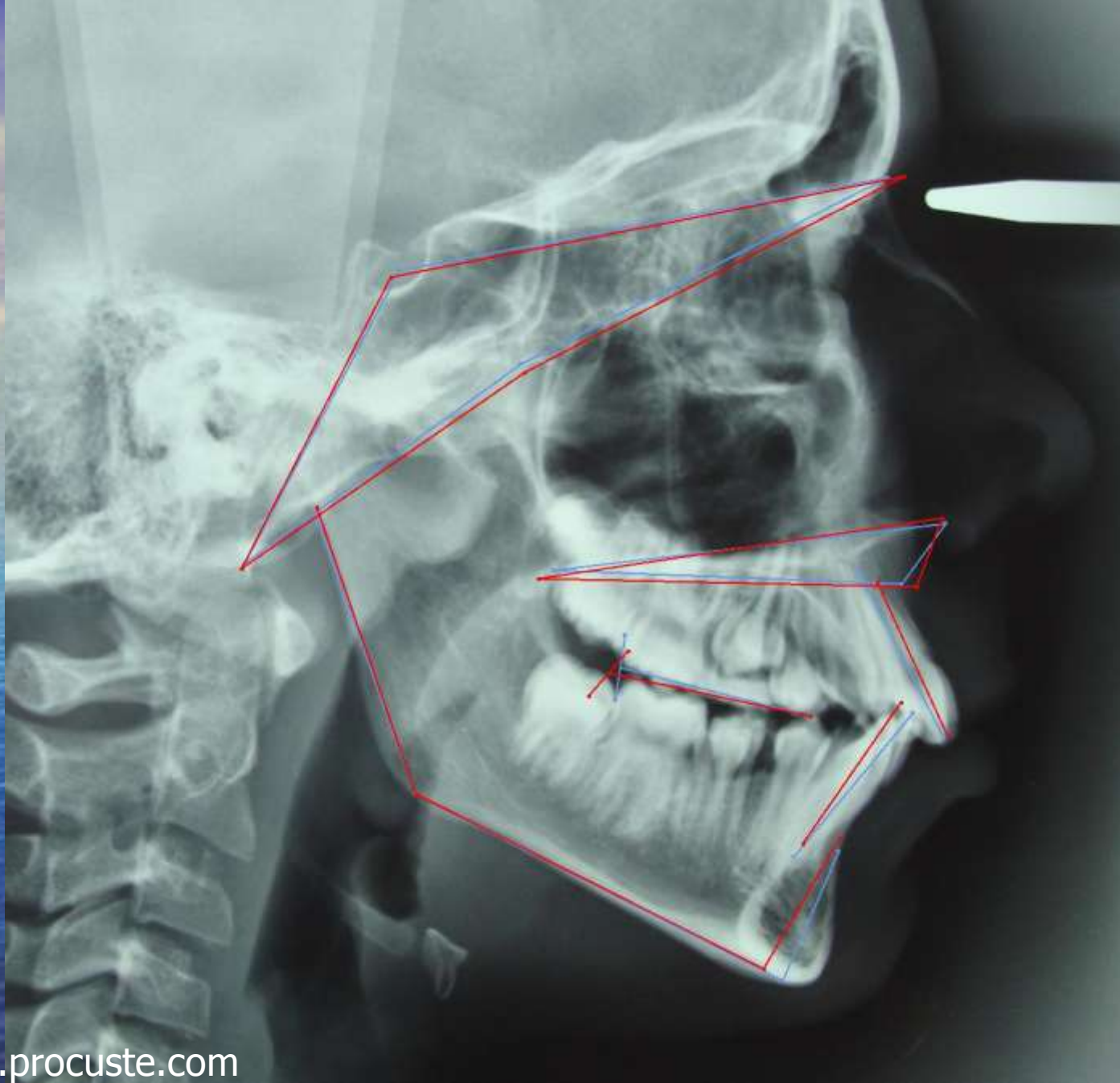
3 Months

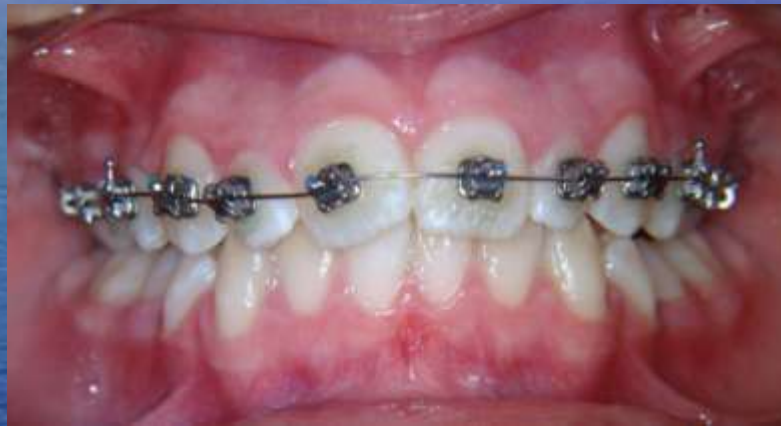Harmonisation 4 D



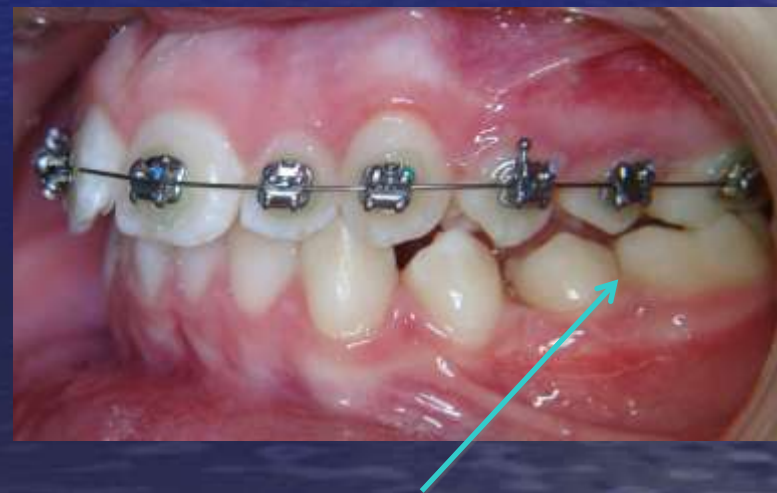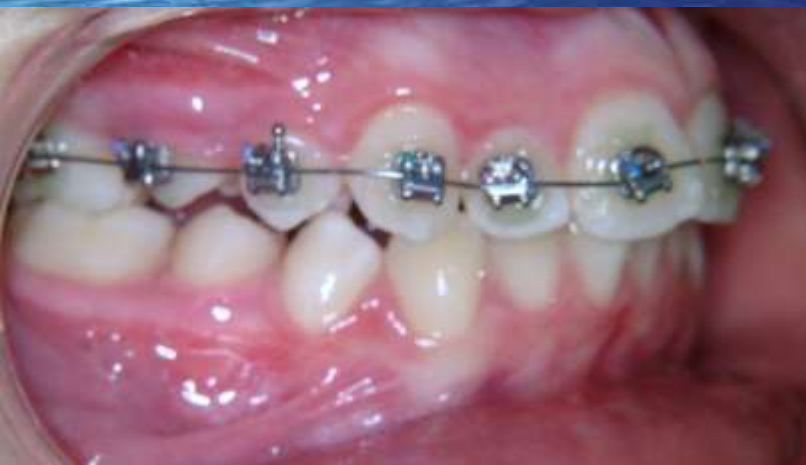6 Months

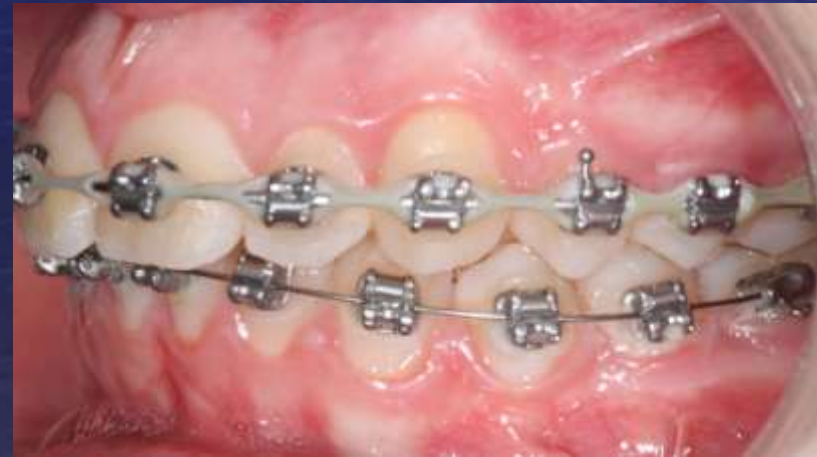
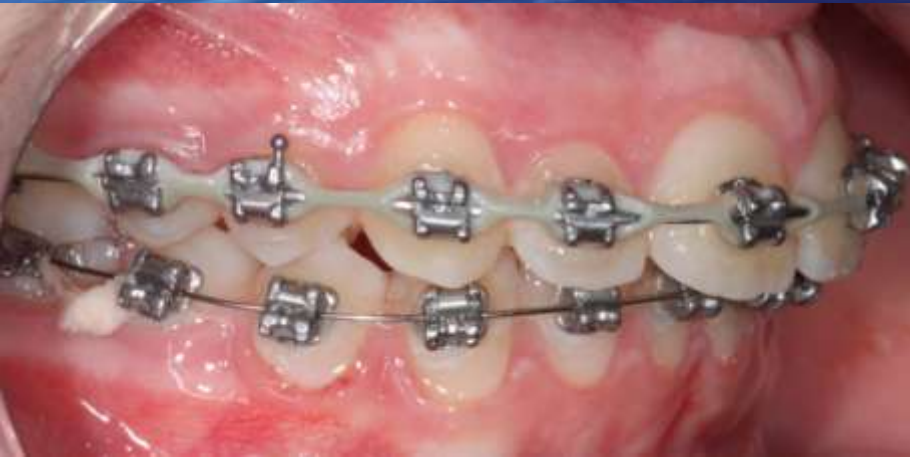
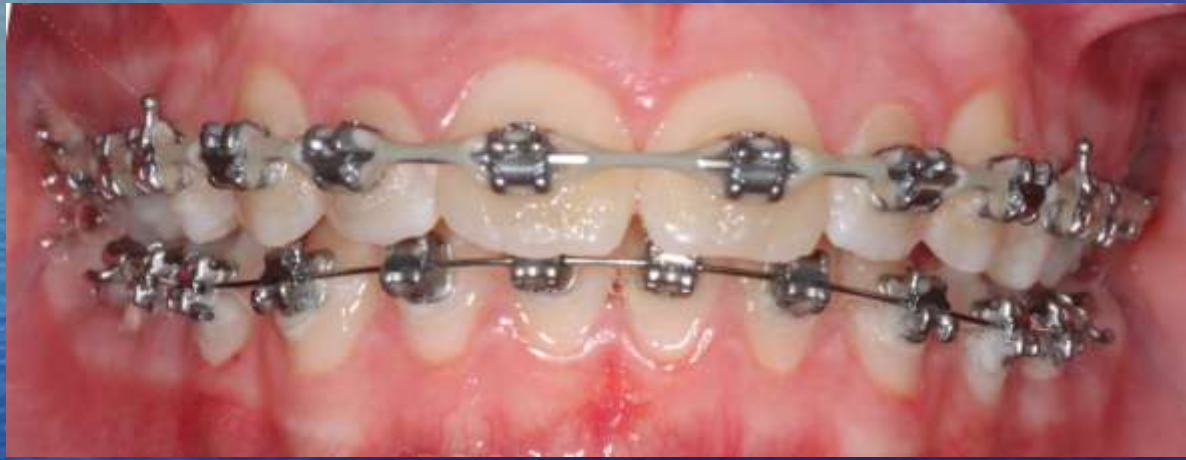

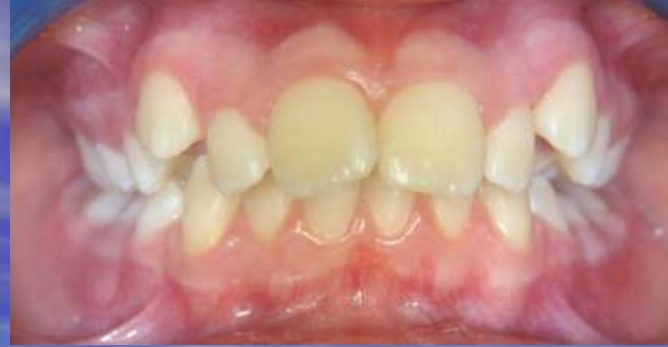

PUL 10 months
Harmonisation 4D

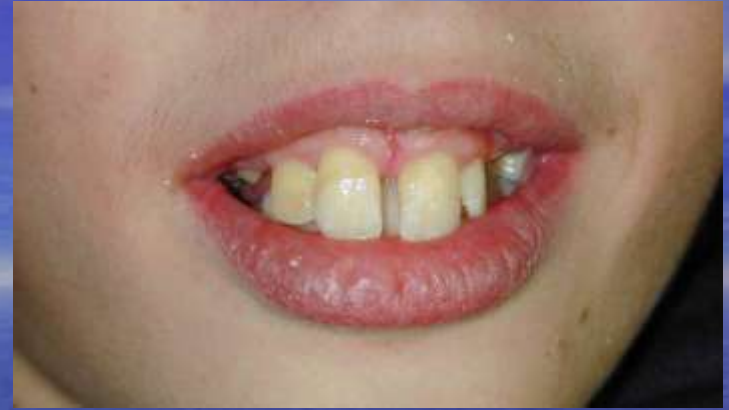
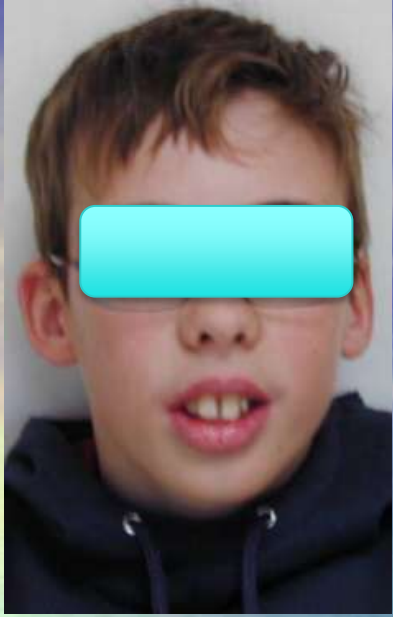




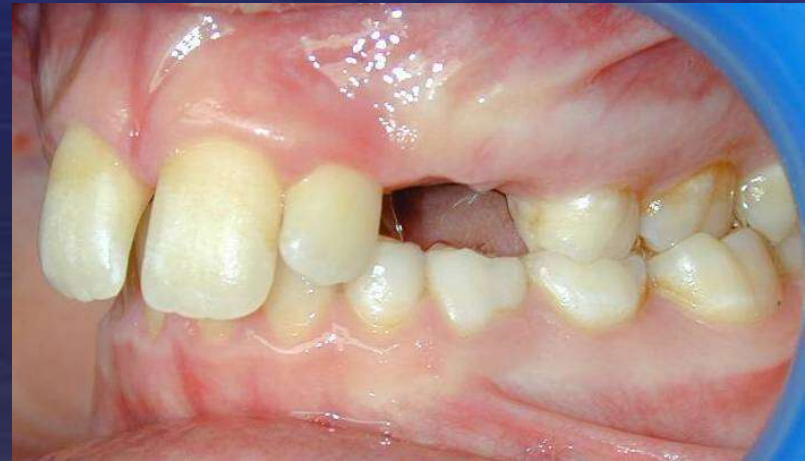
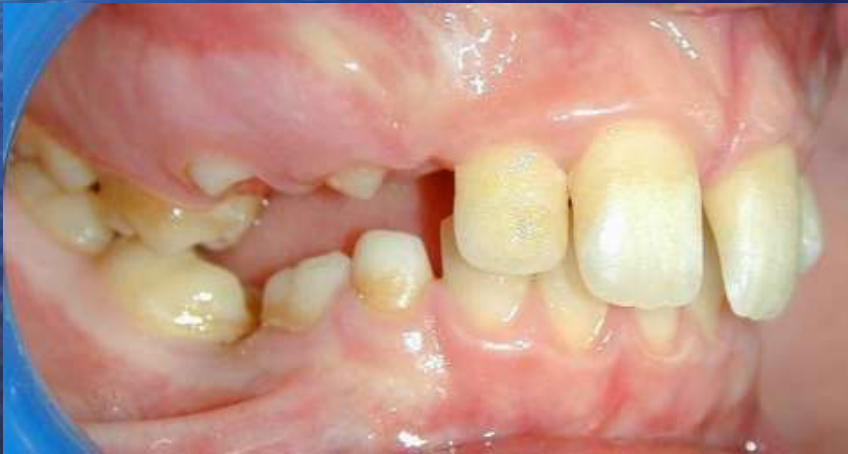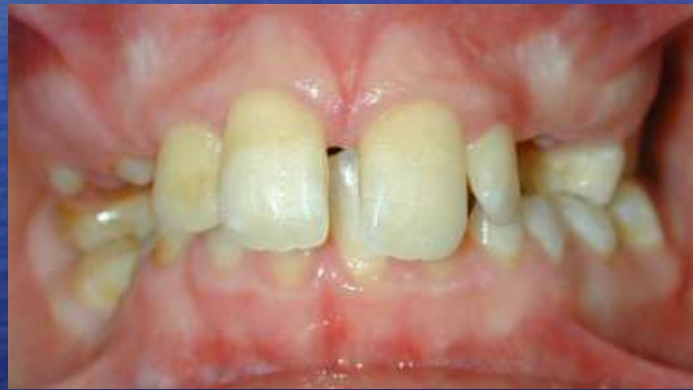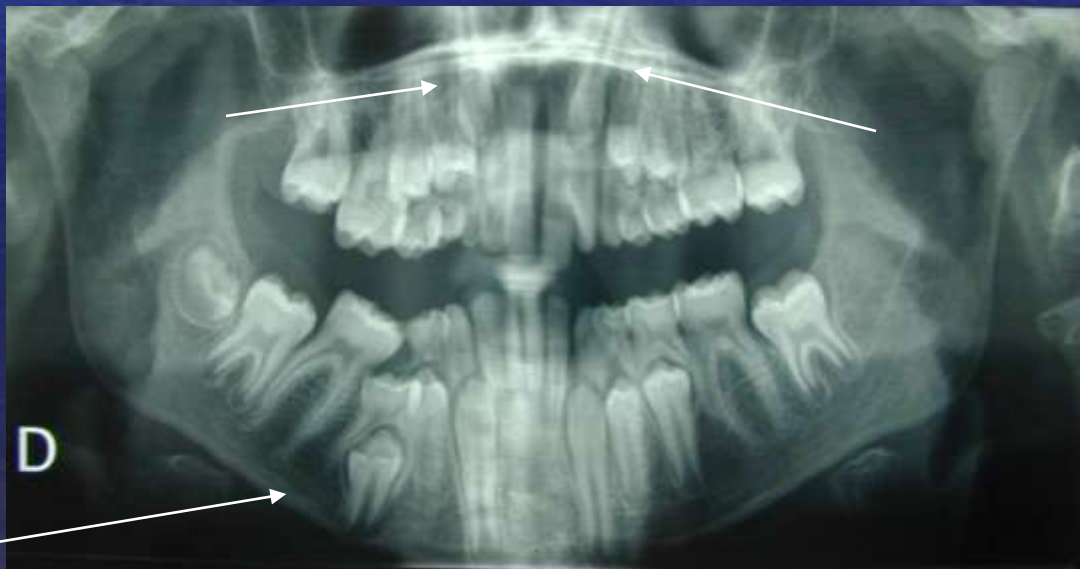
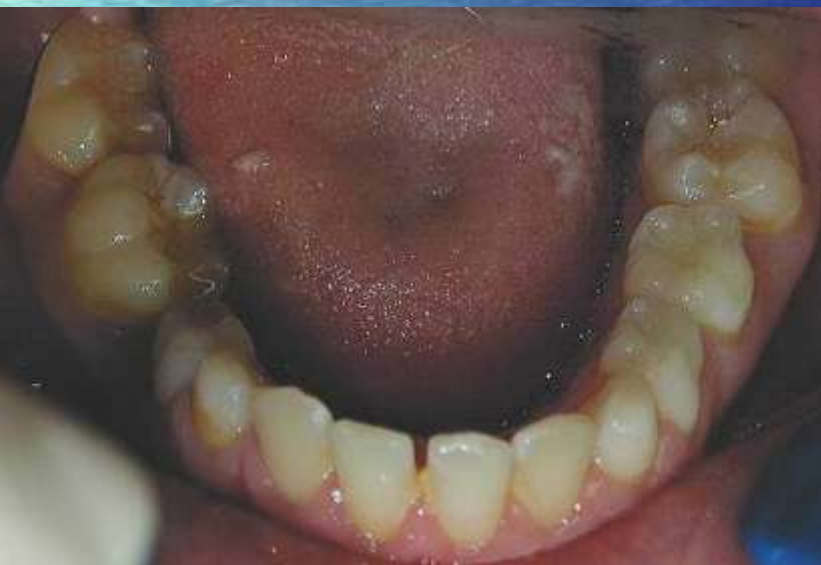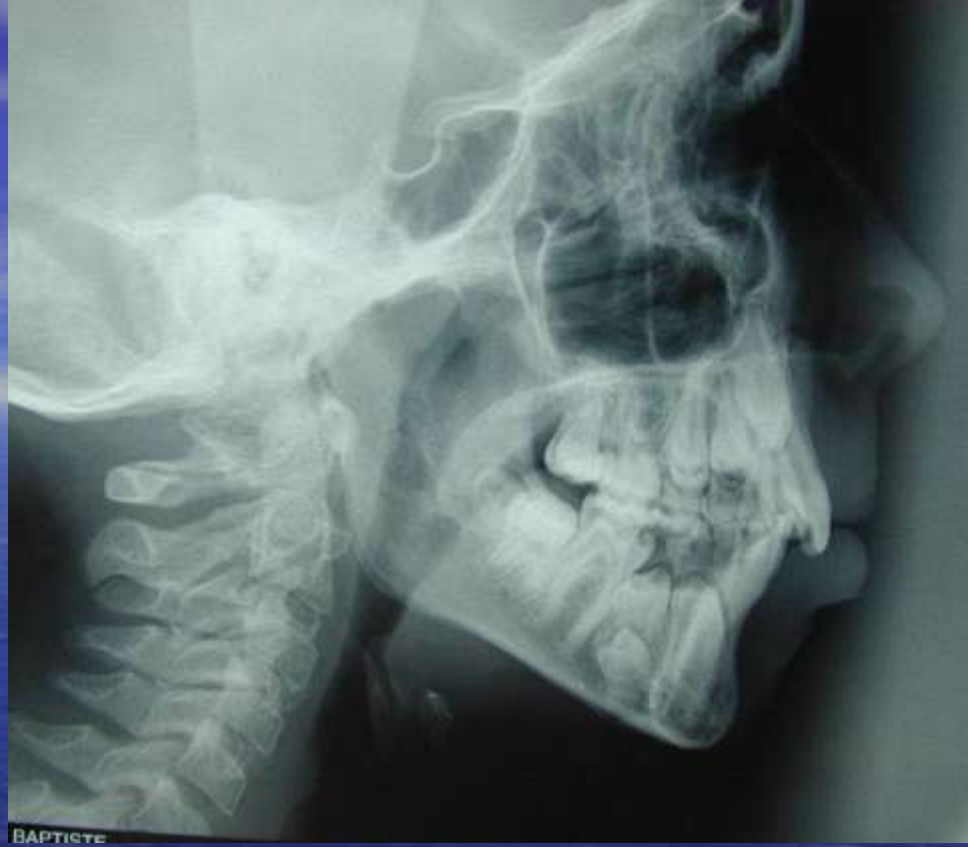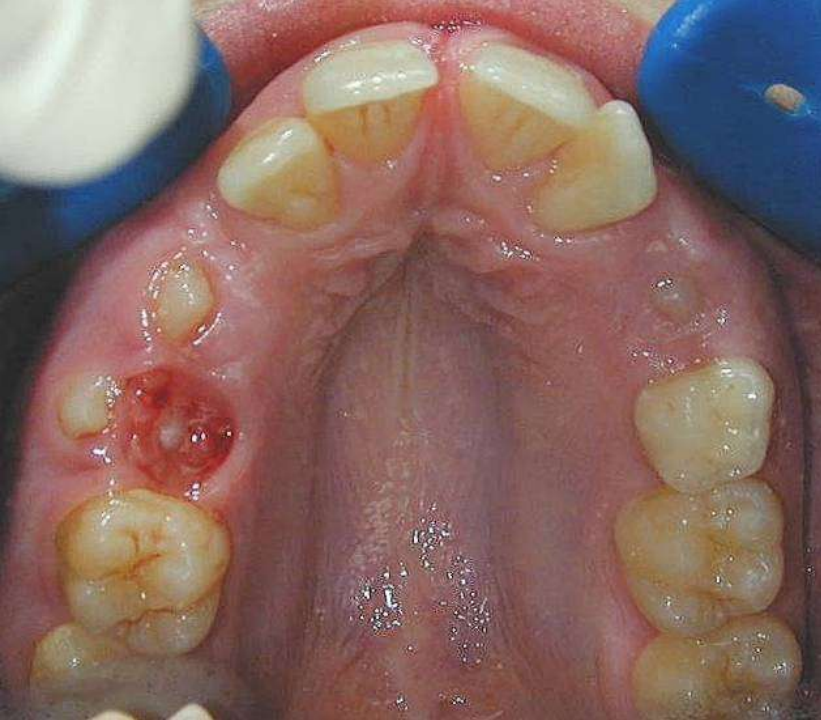Classe II Hyperdivergente

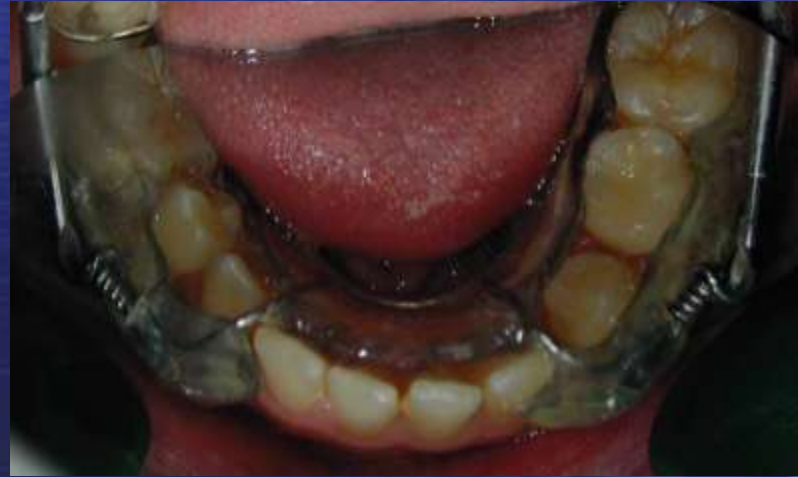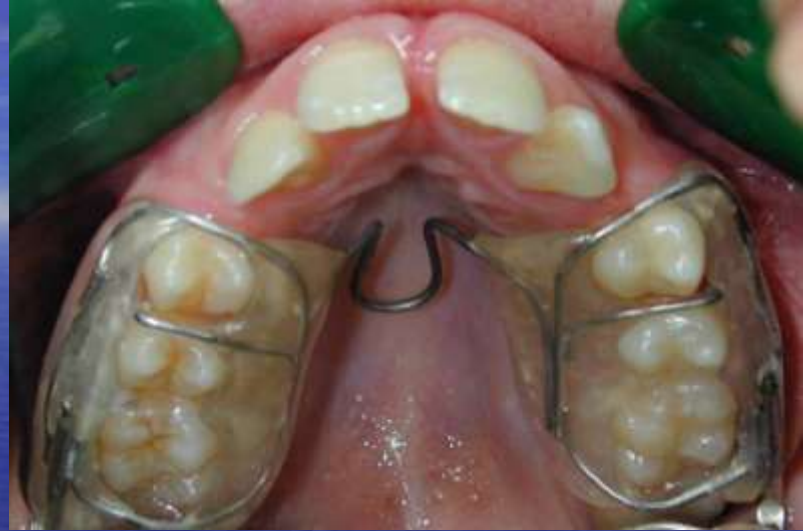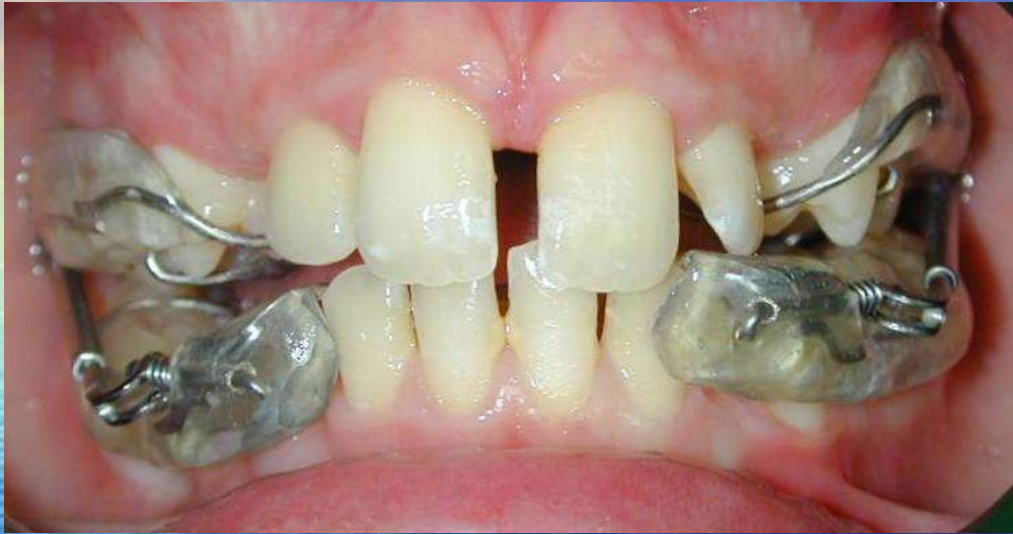Inclusions multiples
PUL + Autoligaturants

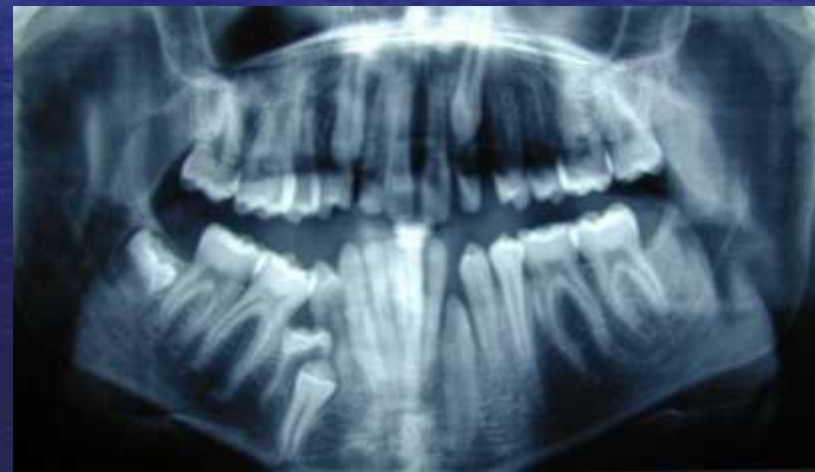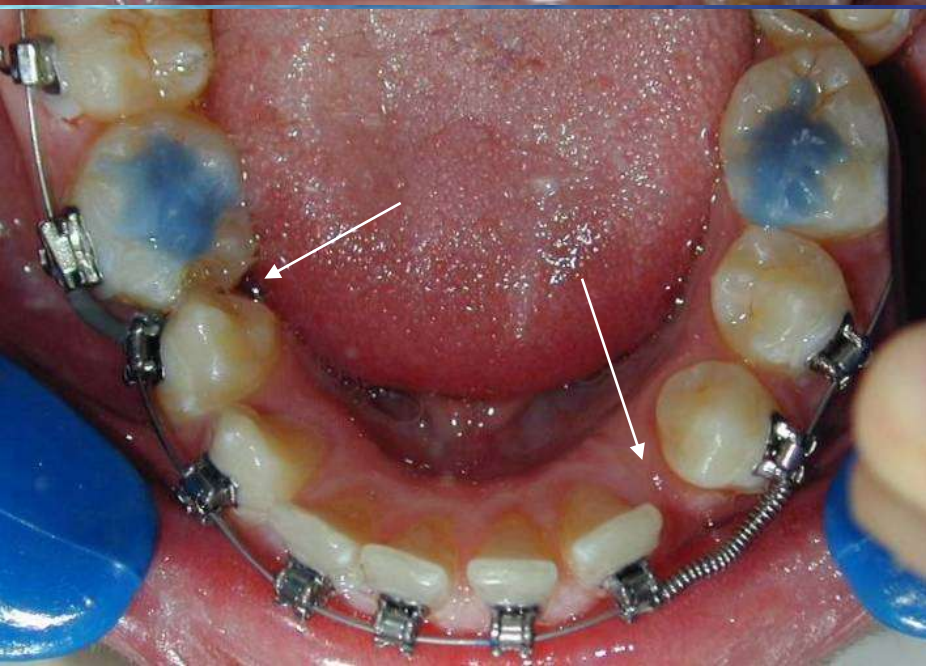

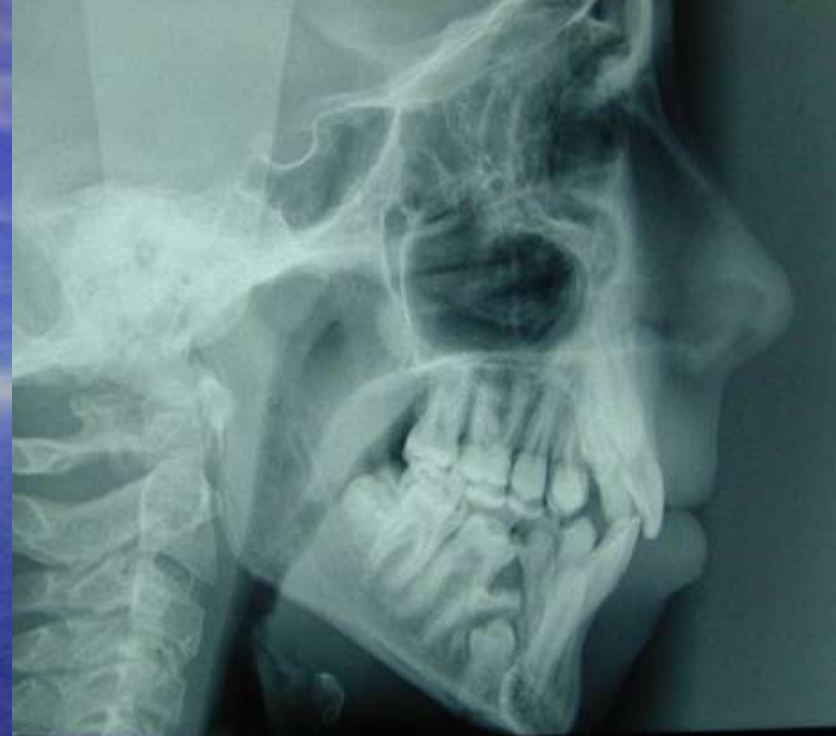
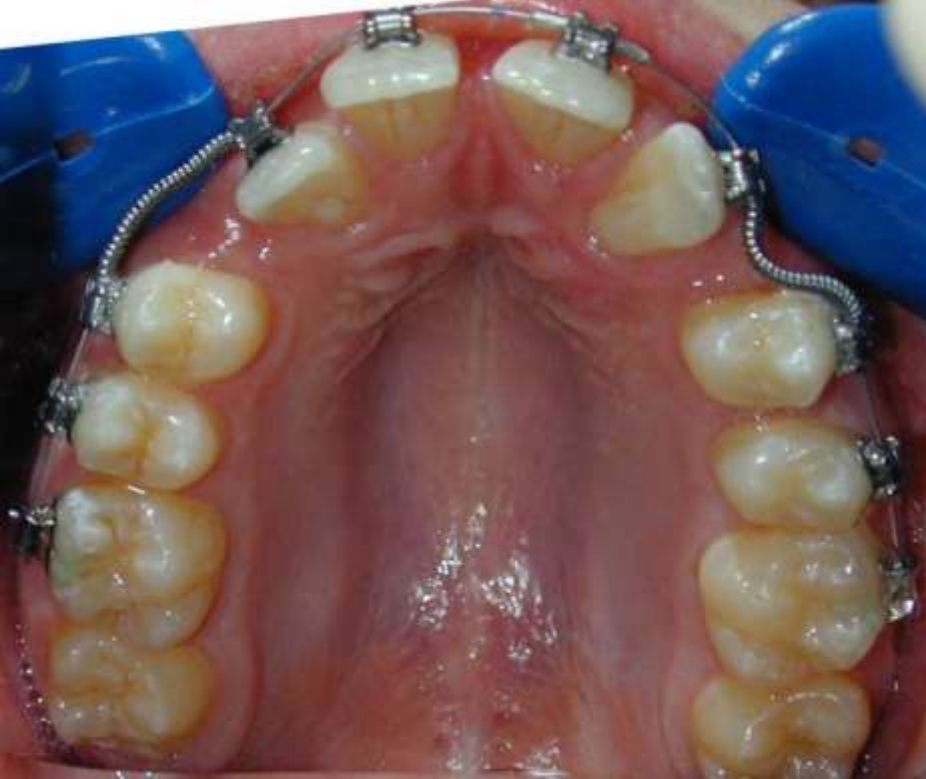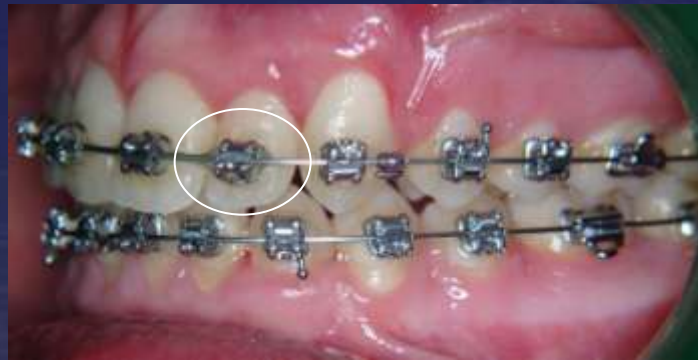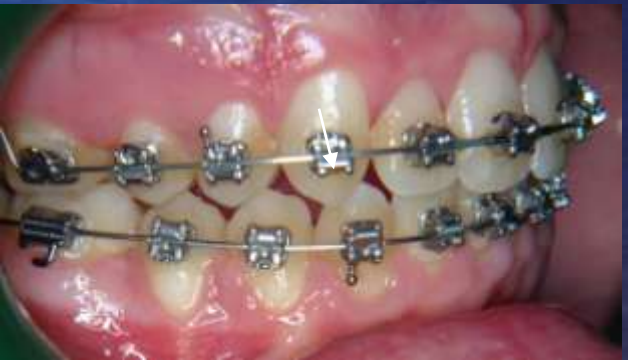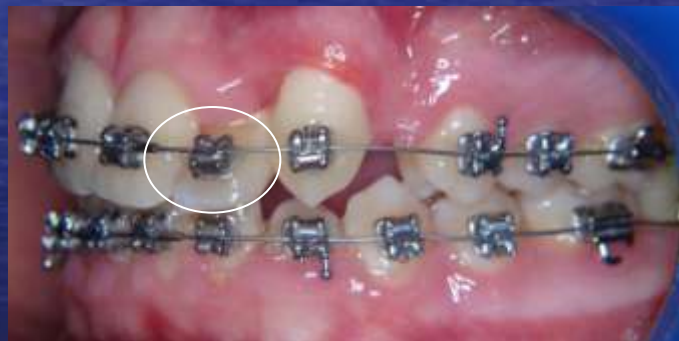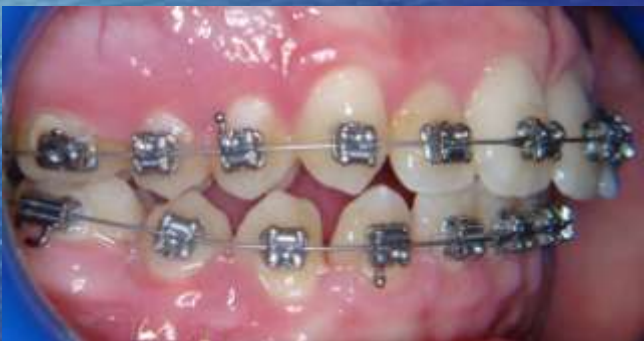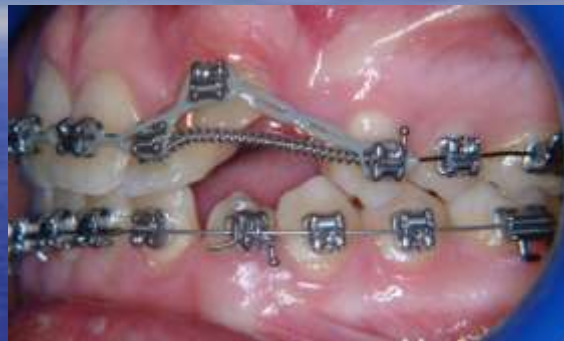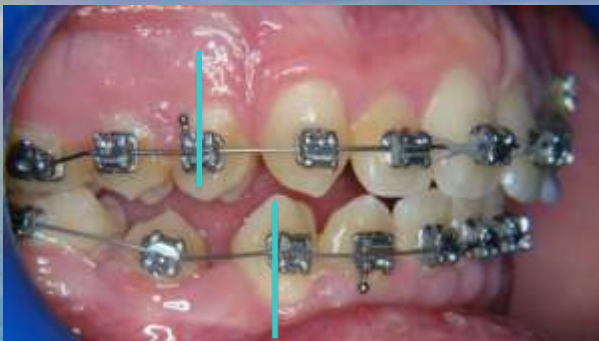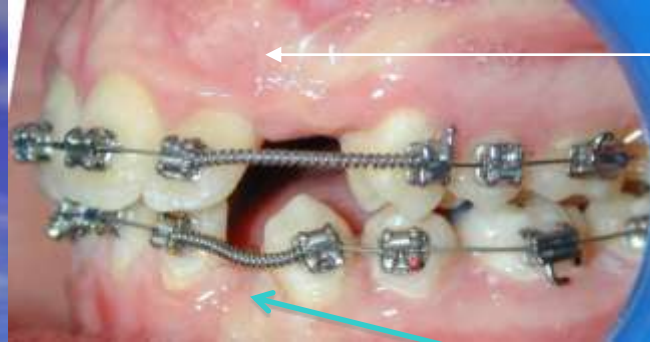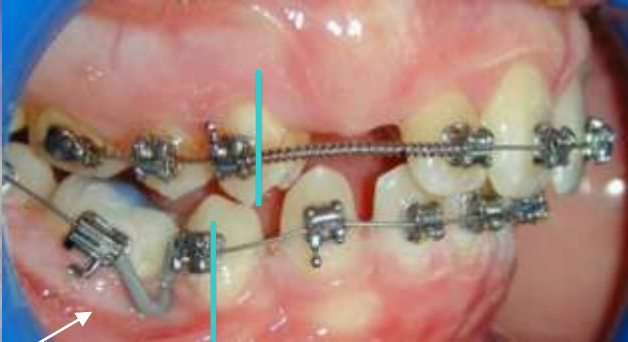Baptiste Hug.
13 ans

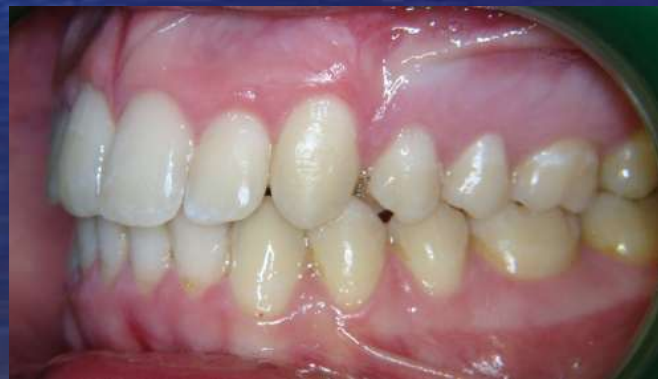
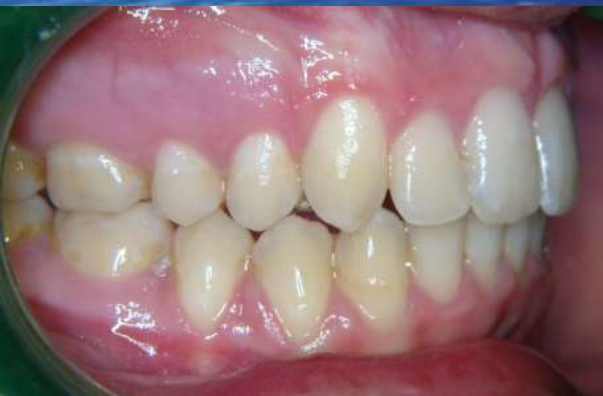
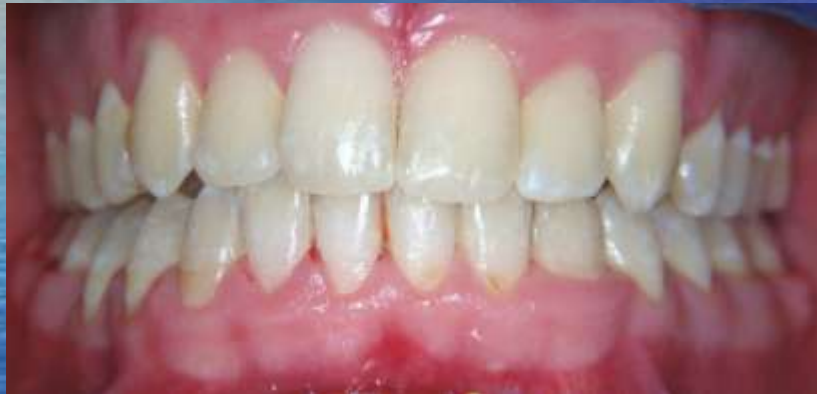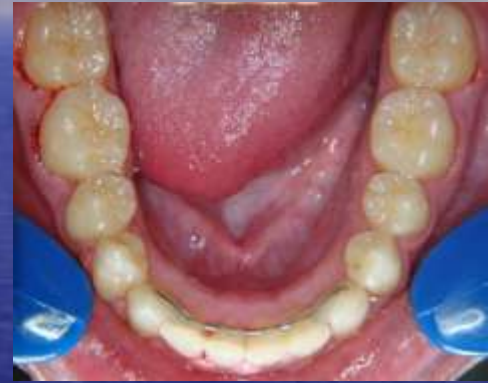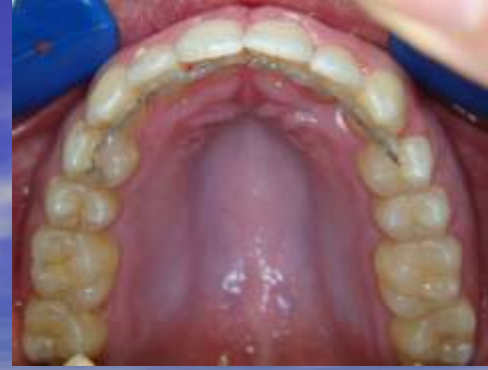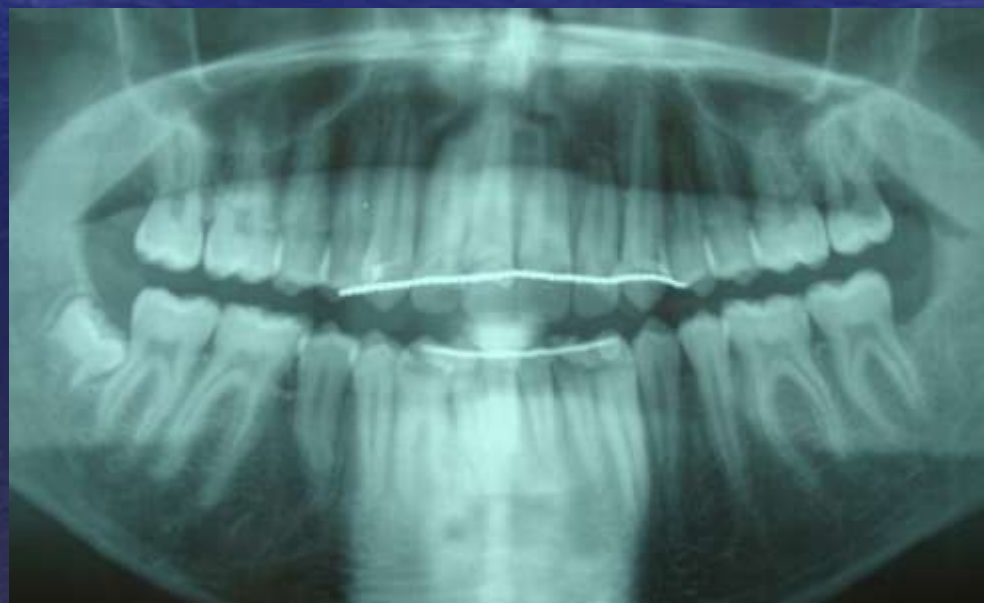


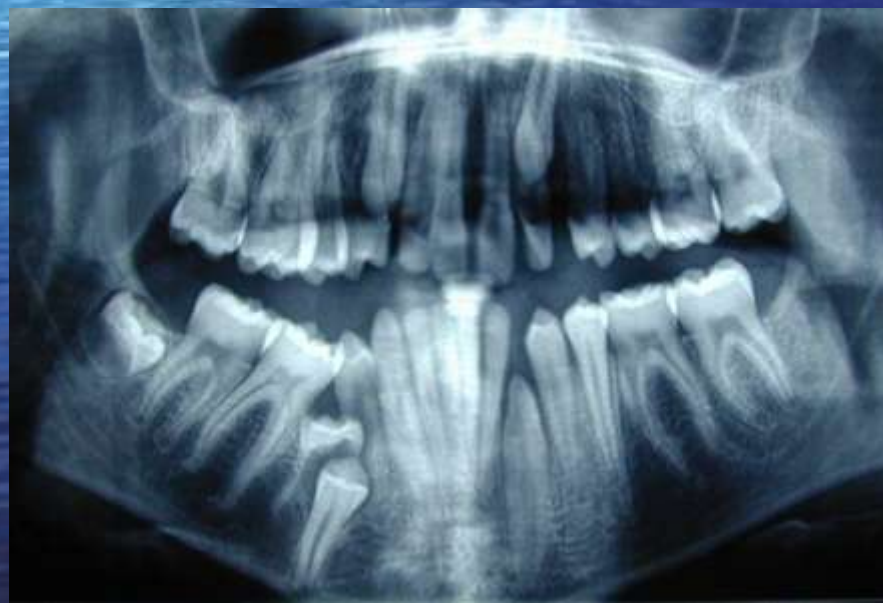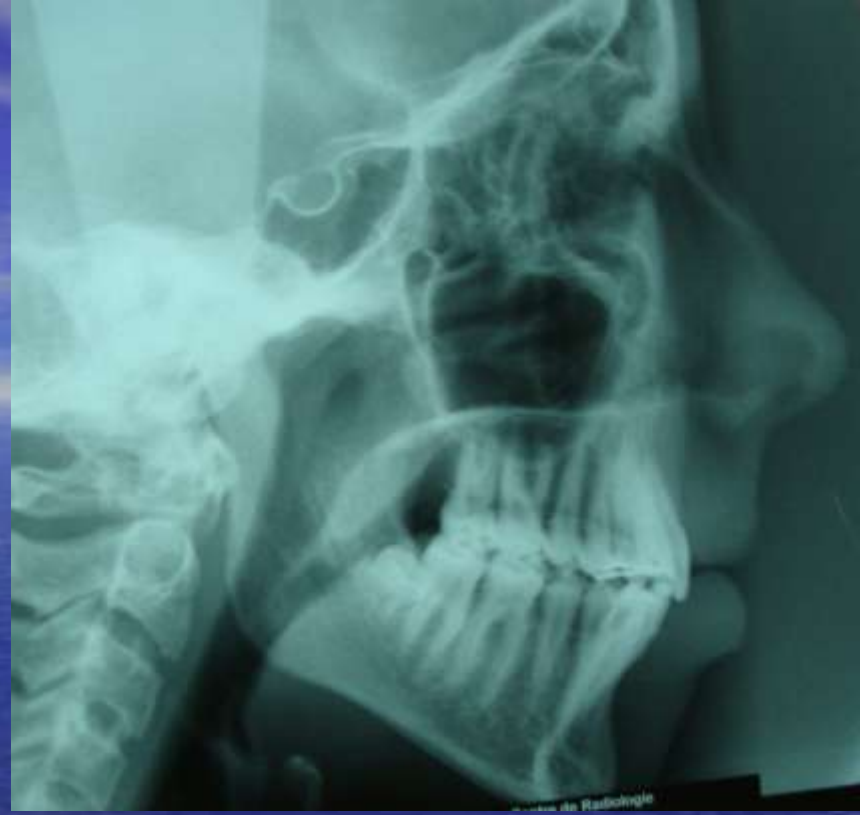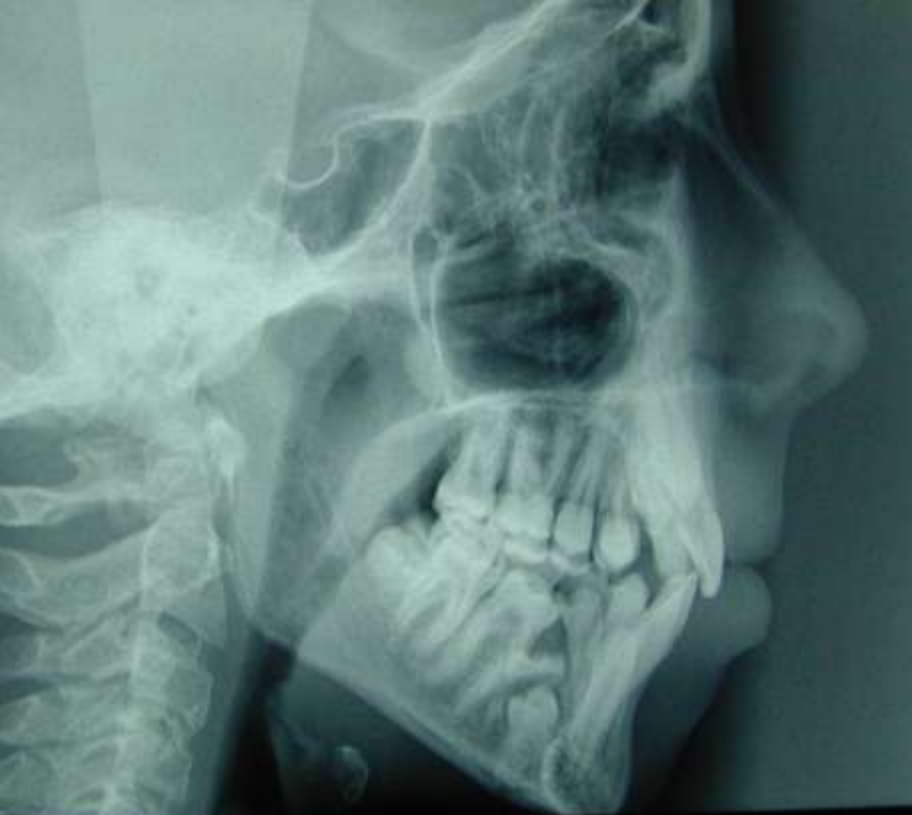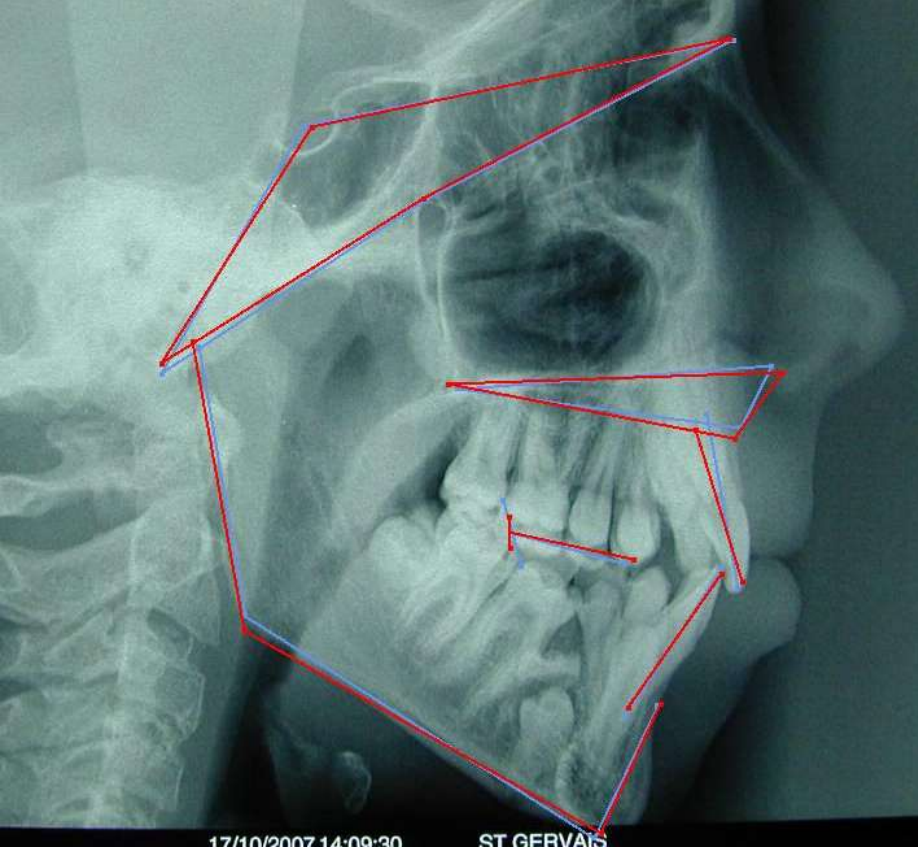




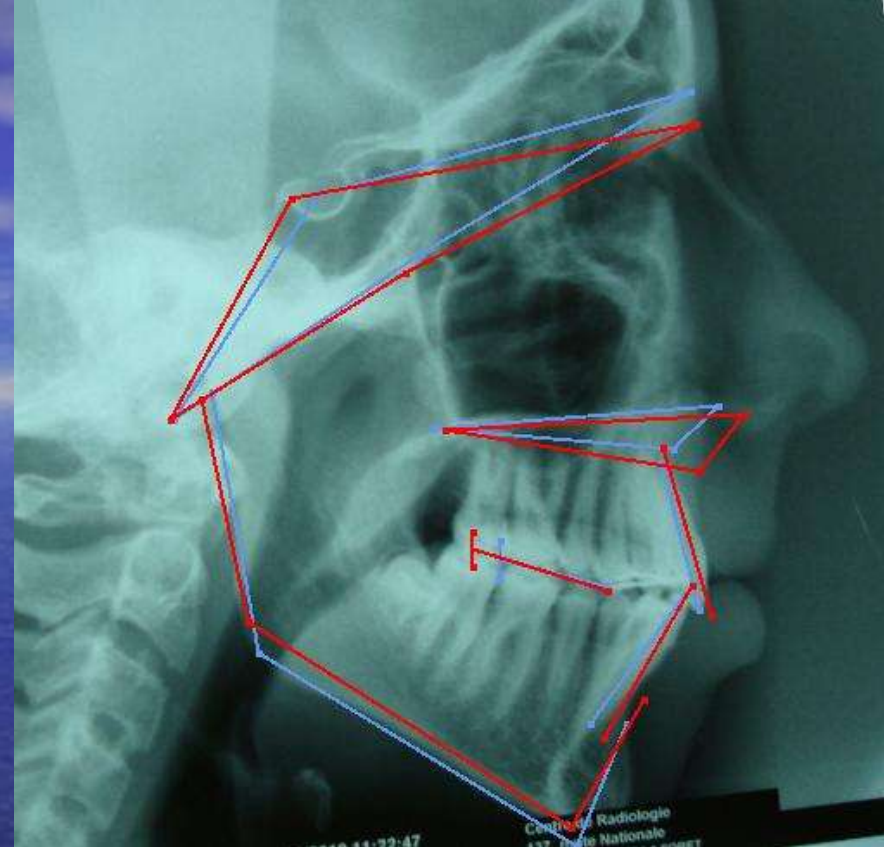








Avant / Apres PUL



Avant / Apres fin



